



Email:

rob.scottmillar@gmail.com

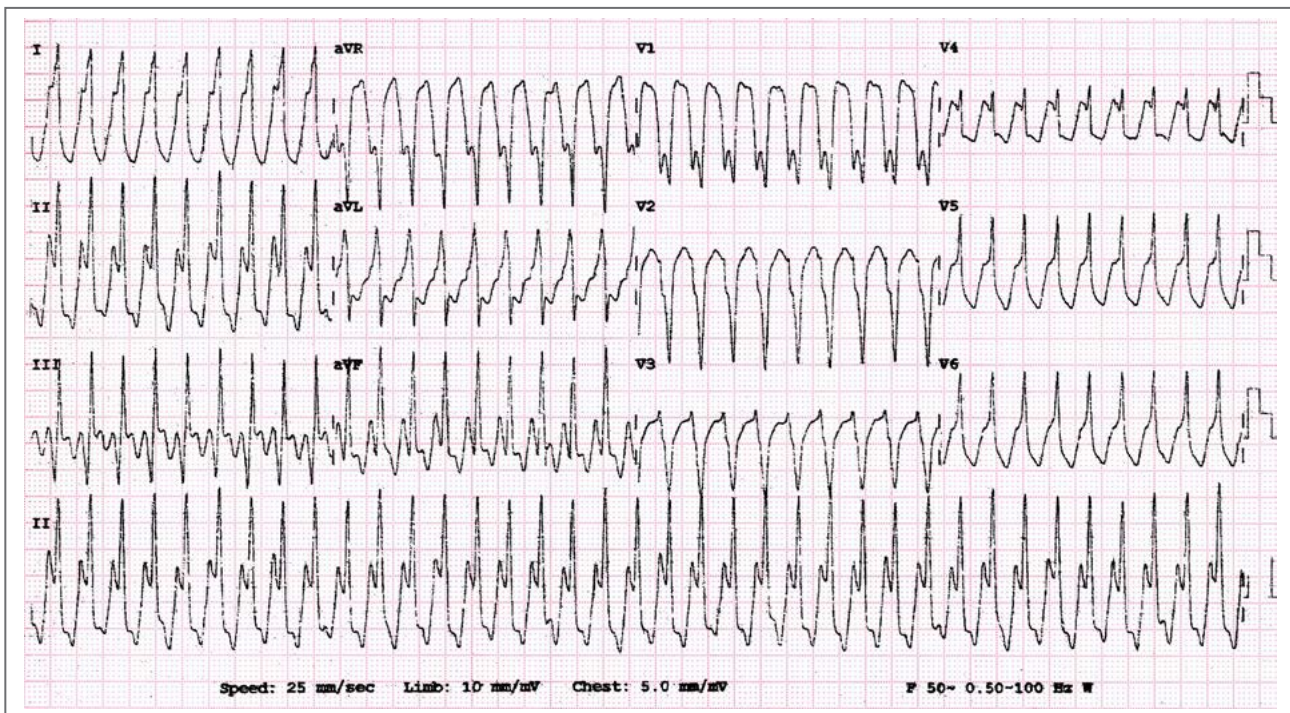
RS Millar  <https://orcid.org/0000-0002-5608-0623>

A Chin  <https://orcid.org/0000-0001-6930-3673>

DOI: <https://doi.org/10.24170/23-2-8287> | <https://doi.org/10.24170/23-2-8288>

Creative Commons License - CC BY-NC-ND 4.0

An 8-year-old boy presents with this arrhythmia.



QUESTION 1: Which one of the following is the best diagnosis?

- a. Ventricular tachycardia (VT).
- b. Supraventricular tachycardia (SVT) with left bundle branch block (LBBB).
- c. Antidromic atrioventricular re-entry tachycardia (AVRT) (Wolff–Parkinson–White [WPW] syndrome).
- d. SVT with non-specific intraventricular conduction delay.

QUESTION 2: What is the most likely clinical diagnosis?

- a. Idiopathic right ventricular (RV) outflow tract (RVOT) tachycardia.
- b. Arrhythmogenic right ventricular cardiomyopathy (ARVC).
- c. Hypertrophic obstructive cardiomyopathy (HOCM).
- d. Post-operative tetralogy of Fallot (TOF).

Please analyse the ECG carefully and commit yourself to an answer before checking the explanation.

ANSWER on page 110