

Tropical endomyocardial fibrosis and rheumatic heart disease: A fortuitous association?

**Matthias Lachaud^{*,#}, Mariana Mirabel^{†,‡,§},
Eloi Marijon^{†,‡,§} and Beatriz Ferreira[#]**

*Institut du Thorax, University Hospital of Nantes, 1 Place Alexis Ricordeau, 44000 Nantes, France

#Instituto do Coração, 1111 Av Kenneth Kaunda, Maputo, Mozambique

†INSERM U970, Paris Cardiovascular Research Centre, PARCC, Paris, France

‡Université Paris Descartes, Sorbonne Paris Cité, Paris, France

§Assistance Publique-Hôpitaux de Paris, Hôpital Européen Georges Pompidou, Paris, France

Address for correspondence:

Matthias Lachaud,
Institut du Thorax
University Hospital of Nantes
1 Place Alexis Ricordeau
44000 Nantes
France

Email:

Lachaud.matthias@gmail.com

A 20-year-old man from Mozambique was admitted for dyspnea. His physical exam showed orthopnea, hepatomegaly and hepatalgia. His blood pressure was 100/70mmHg and heart rate 102bpm. His cardiac auscultation revealed a regular gallop rhythm due to the presence of a third heart sound, a systolic murmur and diastolic rumble.

An electrocardiogram suggested left atrial enlargement with a bifid P wave in lead II and enlarged terminal negative portion of the P wave in lead VI.

Transthoracic echocardiography showed 2 distinct abnormalities: severe mitral stenosis and lesions consistent with advanced right sided endomyocardial fibrosis. The mitral valve had the typical appearance of rheumatic heart valve disease: bicommissural fusion, leaflet thickening being more pronounced at the tips with relative sparing of the midportion resulting in restriction of both leaflets and thickening and shortening of the chordae (Figure 1A). Mitral regurgitation and stenosis were severe with a mean transmitral gradient of 22mmHg and a mitral valve area by planimetry of 0.5cm² (Figure 1B, Video 1).

On the other hand, the right ventricle yielded characteristic abnormalities of tropical endomyocardial fibrosis with obliteration

and retraction of the apex (Figures 1C and 1D, Video 2) and severe biatrial dilatation. Tricuspid regurgitation was deemed moderate with moderately thickened leaflets. The pulmonary arterial systolic pressure was estimated as 45mmHg.

Cardiac surgery was undertaken, including mechanical mitral valve replacement associated with right ventricular endarterectomy. Intra-operative findings confirmed the absence of endomyocardial fibrosis of the left ventricle with a typical aspect of rheumatic mitral valve.

In Africa, rheumatic heart disease remains the main differential diagnosis of tropical endomyocardial fibrosis which has quite different echocardiographic lesions.^(1,2) The association of rheumatic heart disease and tropical endomyocardial fibrosis is rare, but not an exceptional situation in endemic areas for these 2 diseases. That is why some authors have implicated rheumatic heart disease as a potential cause of tropical endomyocardial fibrosis.⁽³⁾ Nevertheless, the ubiquity of rheumatic heart disease compared to tropical endomyocardial fibrosis confinement in some parts of the world, argues against this hypothesis.^(4,5)

In our 10 years' experience we, the surgical staff at the Heart Institute of Maputo in Mozambique, have reported 23 patients with this association (unpublished data). Is that still a fortuitous association?

Conflict of interest: none declared.

REFERENCES

1. Mocumbi AO, Madeira G, Manafe N, et al. Rheumatic heart disease and endomyocardial fibrosis: Distinguishing the etiology of mitral regurgitation in low-resourced areas. *2017*;14(1):36-41.
2. Sliwa K, Damasceno A, Mayosi BM. Epidemiology and etiology of cardiomyopathy in Africa. *Circulation* 2005;112(23):3577-83.
3. Shaper AG. Endomyocardial fibrosis and rheumatic heart-disease. *Lancet* 1966;1(7438):639-41.
4. Grimaldi A, Mocumbi AO, Freers J, et al. Tropical endomyocardial fibrosis: Natural history, challenges, and perspectives. *Circulation* 2016;133(24):2503-15.
5. Kutty VR, Abraham S, Kartha CC. Geographical distribution of endomyocardial fibrosis in south Kerala. *Int J Epidemiol* 1996;25(6):1202-7.

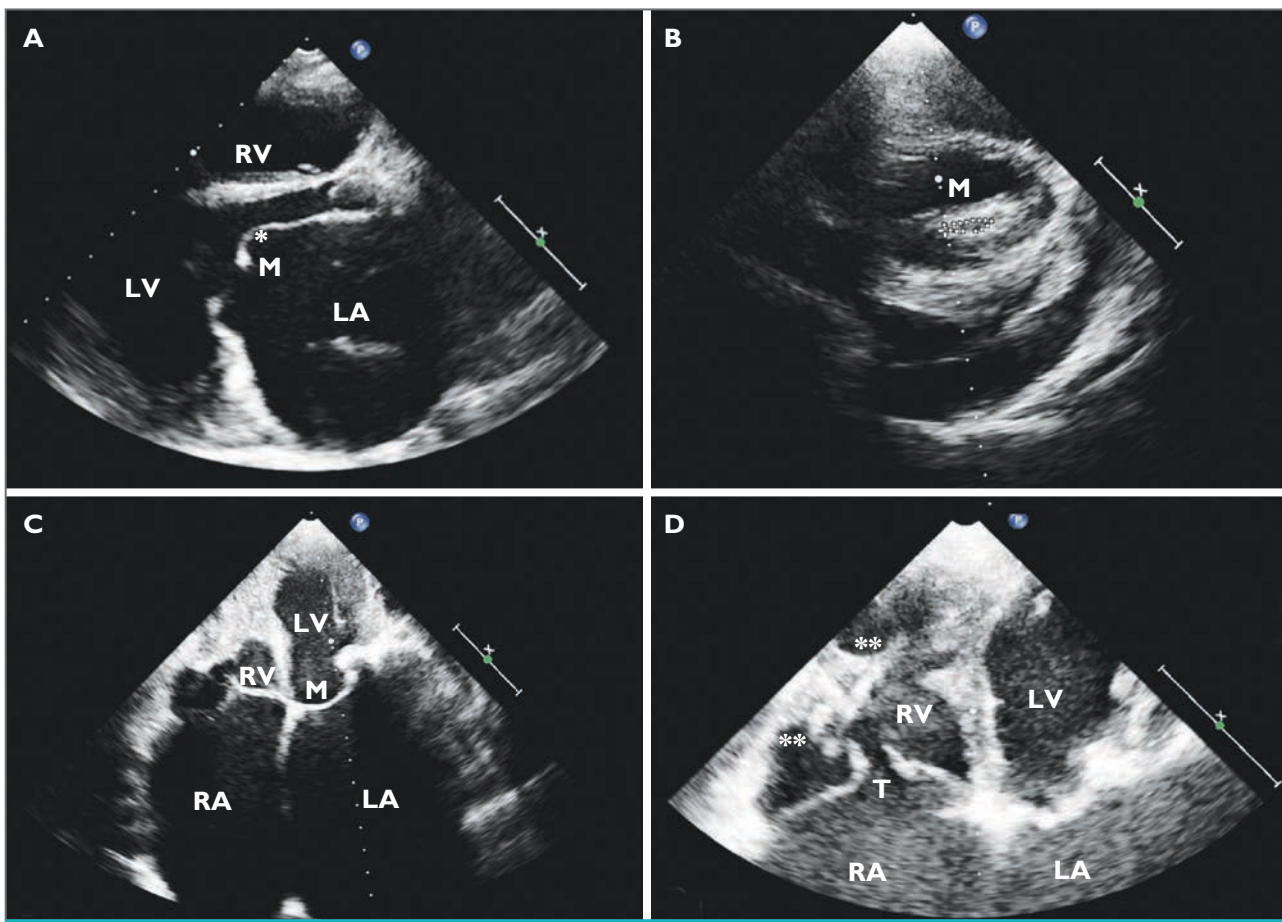


FIGURE 1A: 2D echocardiogram in parasternal long axis view with markedly enlarged left atrium (LA).The mitral valve (M) had a restriction of both leaflets with thickening at the tips of leaflets strongly suggesting a rheumatic heart valve disease.
1B: 2D echocardiogram in parasternal short axis view showing a severe mitral stenosis with bilateral commissural fusion and a mitral valve area by planimetry of 0.5cm².
1C and 1D: 2D echocardiogram in 4 chamber view with a severe fibrosis obliteration and retraction of the right ventricle (RV) pointing towards a diagnosis of tropical endomyocardial fibrosis. Left (LA) and right atriums (RA) are especially dilated.

M = Mitral Valve, T = Tricuspid Valve, LV = Left Ventricle, RV = Right Ventricle, LA = Left Atrium, RA = Right Atrium, *Anterior Mitral Leaflet, ** Endomyocardial Fibrosis.

