

ECG Quiz 7

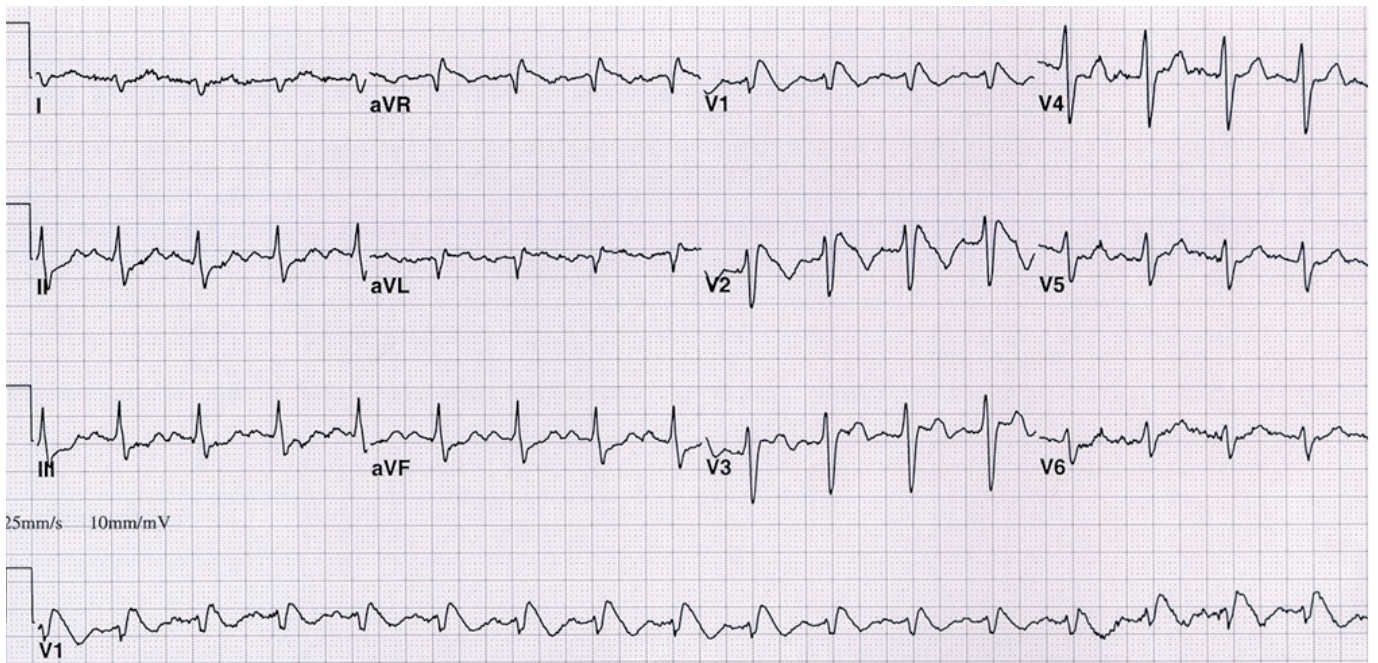


CASSA
CARDIAC ARRHYTHMIA SOCIETY
OF SOUTHERN AFRICA
A SPECIAL INTEREST GROUP OF SA HEART ASSOCIATION

A Okreglicki

Cardiac Clinic University of Cape Town / Groote Schuur Hospital

Cardiac Arrhythmia Society of Southern Africa (CASSA)



A 30 year-old woman was admitted to the emergency unit without escorts but with a story from the paramedics that she had been found by her friend unresponsive and lying on her bed. She was unconscious (GCS 4/15) with dilated pupils, general hyperreflexia, no neck stiffness, afebrile, no skin lesions, very shallow respiration, quiet chest, pulse 110 regular, BP 80/45, heart sounds normal and soft abdomen. There was no evidence of trauma. An ECG was done.

QUESTION: Which ONE of the following conditions is most likely?

- | | |
|--|--|
| (a) Antero-septal myocardial infarction | |
| (b) Intracranial pathology (such as subarachnoid haemorrhage, other bleed) | |
| (c) Post-ictal state with side-effects of anti-epileptic agent | |
| (d) Brugada syndrome | |
| (e) Poisoning or drug toxicity | |
| (f) Metabolic / electrolyte abnormalities. | |

Please analyze the ECG carefully and commit yourself to an answer before checking the explanation.

ANSWER on page 48