

ECG Quiz 8

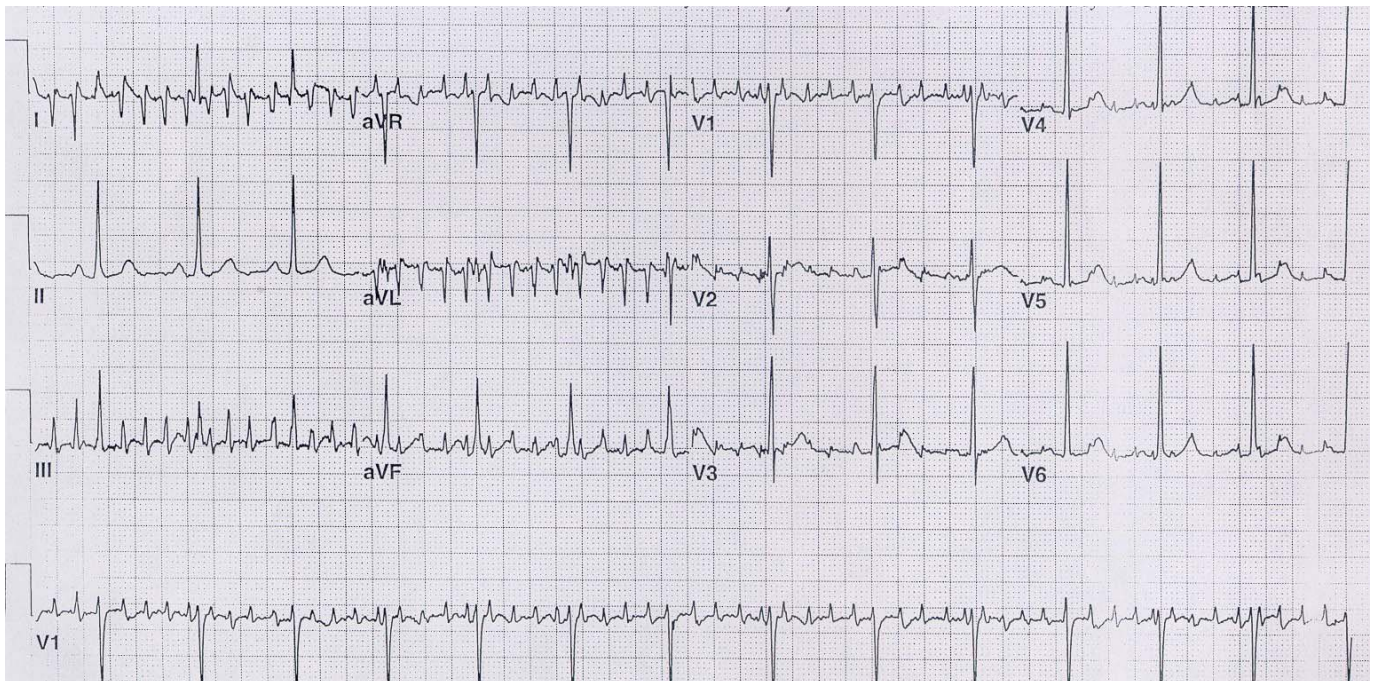


CASSA
CARDIAC ARRHYTHMIA SOCIETY
OF SOUTHERN AFRICA
A SPECIAL INTEREST GROUP OF SA HEART ASSOCIATION

A Okreglicki

Cardiac Clinic University of Cape Town / Groote Schuur Hospital

Cardiac Arrhythmia Society of Southern Africa (CASSA)



This is an ECG of a 53-year-old woman. She has never had heart surgery.

QUESTION: Which ONE of the following is the best treatment?

- | | |
|---|--|
| (a) Cardioversion | |
| (b) Beta-blockers | |
| (c) Levodopa | |
| (d) Pacemaker | |
| (e) Electrophysiological study and ablation procedure | |

Please analyze the ECG carefully and commit yourself to an answer before checking the explanation.

ANSWER on page 46