

The ECG shows a regular bradycardia with a ventricular rate of 48 bpm.

The main other observations related to the QRS complexes are:

- QRS width: all the QRS complexes are wide and similar in morphology (as seen in the bottom V1 rhythm strip). Width = 120ms (normal is up to 100ms or 2.5 little blocks).
- QRS axis: approximately 0° (normal in adult is -30 to +90°).
- QRS morphology: In V1: QS waves. In the high lateral leads, I and aVL: wide R waves. This is closest to a Left Bundle Branch Block (LBBB)-like pattern; yet it is not typical LBBB.

**Having observed a bradycardia, the immediate question that this raises is: What is the mechanism of the bradycardia?**

This requires careful analysis of the atrial activity in order to decide which one of 2 possible mechanisms is in operation:

- i) a disorder of impulse formation: normal atrial activity would not be observed. There may be no P waves or they may be very slow in rate.
- ii) a disorder of impulse conduction: atrial activity is observed that may be normal but which is not conducted normally to the ventricles.

Analysis of this ECG shows that there are indeed P waves. These appear to have normal P wave morphology and axis in keeping with sinus node origin. So, P wave formation is occurring but is it normal? To answer this, we must examine the P wave rate: if it is 48 bpm then it is not normal.

Before we determine the exact P wave rate, it may have been observed that there is no normal P to QRS relationship. Yes, on this recording there happens to be a P in front of each QRS but this P to QRS interval or apparent "PR" interval is not only long but variable and is actually getting shorter. In Wenckebach AV block, the PR intervals do change but this change is the reverse of what is observed here, i.e. the PR gets longer. The answer therefore is not (e).

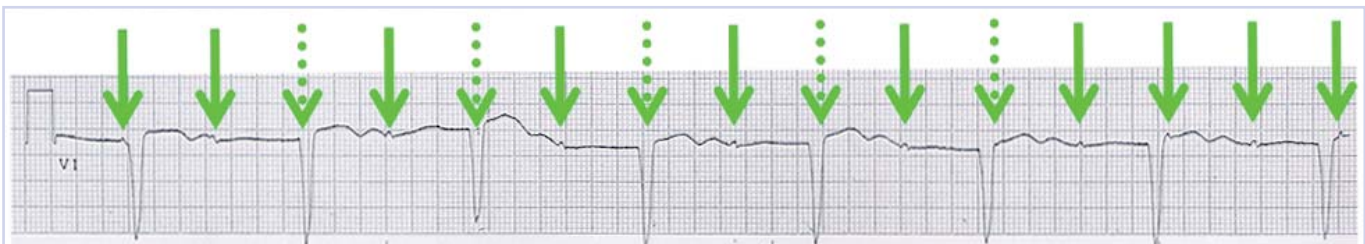
Well, is it then sinus bradycardia with a long but variable PR interval? If it is interpreted that the patient does have sinus bradycardia, he must clearly

have more than that to account for the abnormal conduction and no normal PR intervals. Careful observation, however, shows that the P wave rate is not slow but in fact  $15 \times 6 = 90$  bpm. Observe in the V1 rhythm strip, the P wave right on the beginning of the first QRS complex and the P waves immediately after the second last and last QRS complexes. Using the P-P intervals we can plot or march out the atrial activity (see Figure 1) and clearly see that the patient is in normal sinus rhythm, i.e. normal P wave formation with normal rate. The P waves and QRS complexes are dissociated and there is no evidence that any of the P waves is conducted. The answer therefore is complete AV block or (b). This is not hyperkalemia, which is usually associated with disordered impulse formation rather than atrial impulse conduction.

The QRS complexes are abnormal and represent an escape rhythm arising from below the level of the AV block. Being wide with abnormal morphology, it is likely that this escape rhythm is of ventricular origin. If so, it is not possible to comment on and analyze the QRS morphology with respect to localization of possible infarction. Therefore answer (d) is incorrect.

Question 2 asks about the risks associated with this patient's complete heart block. Yes, he is at risk of syncope. This could be due to ventricular asystole which could occur should the ventricular escape rhythm fail. Not everyone has an escape rhythm. Obviously this man is a survivor as he is fortunate to have an escape rhythm; if he had had no escape rhythm, he would have died suddenly and never presented to a doctor.

There is one further very important observation that is often overlooked: the QT interval. In this ECG, the QT interval is exceedingly long: in V1 or V3 it is more than  $3\frac{1}{2}$  big blocks wide and measures 720ms. Even taking into account that the wide QRS and the slow rate may be contributory factors for lengthening of the QT, this QT is remarkably long. Furthermore the T waves have a very abnormal morphology. In V1, a clear notch giving a bifid T wave is seen. The second component of the T in V1 is not a U wave which requires that the interval between a T and U wave reach baseline which is not what is noted here (see Figure 2) With this extraordinarily long



**FIGURE 1:** The V1 rhythm strip displaying the underlying sinus rhythm at 90 bpm. The green solid arrows indicate the P waves; the dotted arrows indicate where the regular sinus rhythm P waves can be mapped to and which are obscured by QRS complexes.

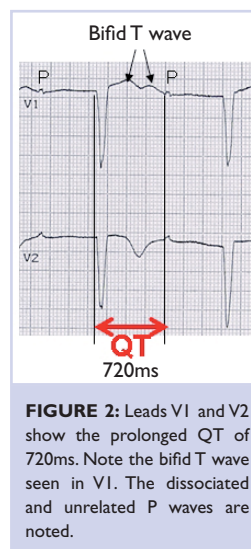
QT, this man is at risk of "long QT"-related polymorphic ventricular tachycardia or Torsade de Pointes. This "bradycardia-induced-tachycardia" is very unstable and terminates spontaneously back to the underlying rhythm or degenerates into ventricular fibrillation. Thus, the patient is at risk of not only syncope but sudden cardiac death. The answer regarding the risk is (d) or all the above.

In view of i) the potential of unpredictable failure of the ventricular escape rhythm and ii) recognizing the risk of ventricular tachycardia, this patient must be under continued observation while awaiting urgent pacing, which will eliminate both. He in fact developed Torsade en route to the cath lab for pacing (see Figure 3).

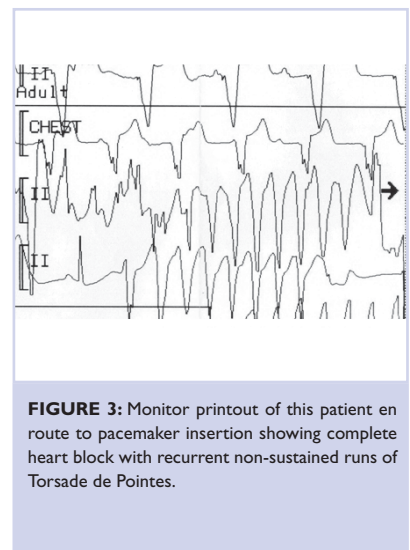
## CONCLUSION

In any bradycardia, one must assess atrial activity and decide if the bradycardia is due to abnormal impulse formation or abnormal conduction.

In complete heart block, the patient may be at risk of both asystole and ventricular tachyarrhythmia. This knowledge must influence immediate management.



**FIGURE 2:** Leads V1 and V2 show the prolonged QT of 720ms. Note the bifid T wave seen in V1. The dissociated and unrelated P waves are noted.



**FIGURE 3:** Monitor printout of this patient en route to pacemaker insertion showing complete heart block with recurrent non-sustained runs of Torsade de Pointes.