

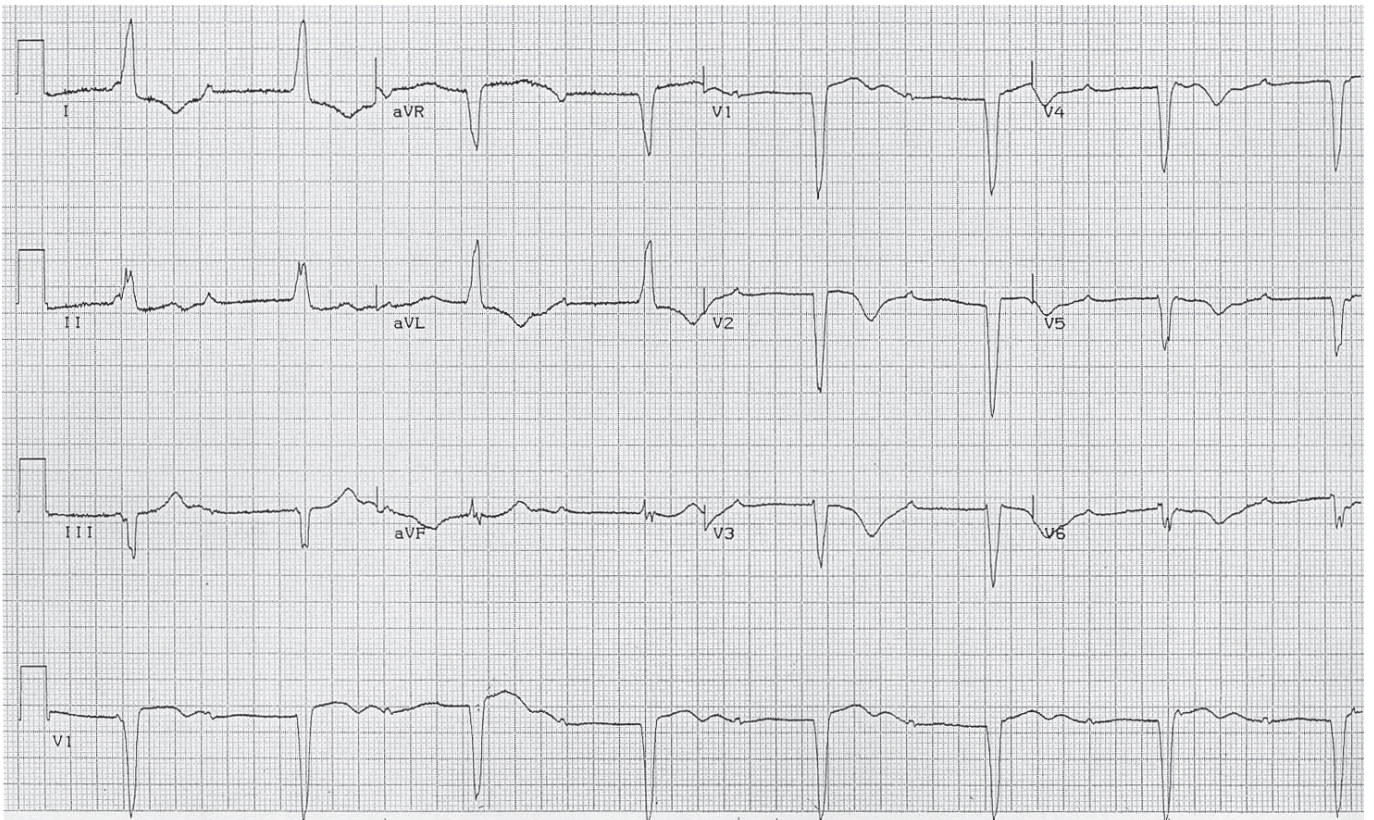
# ECG Quiz 12



CASSA  
CARDIAC ARRHYTHMIA SOCIETY  
OF SOUTHERN AFRICA  
A SPECIAL INTEREST GROUP OF SA HEART ASSOCIATION

**A Okreglicki**

**Cardiac Clinic University of Cape Town / Groote Schuur Hospital  
Cardiac Arrhythmia Society of Southern Africa (CASSA)**



A 76-year-old man has new complaints of feeling very tired and short of breath with minimal exertion.

**QUESTION 1:** Which ONE of the following is the best ECG diagnosis?

- (a) Hyperkalemia
- (b) Complete AV heart block
- (c) Sinus bradycardia with first degree heart block
- (d) Fully evolved extensive anterior myocardial infarction
- (e) Second degree Wenckebach AV block.

**QUESTION 2:** Is this patient at risk? Which of the following risks applies?

- (a) Syncope
- (b) Ventricular asystole
- (c) Ventricular tachyarrhythmia
- (d) All of the above
- (e) None of the above.

Please analyze the ECG carefully and commit yourself to an answer before checking the explanation.

**ANSWER** on page 134