

When dealing with a tachycardia one cannot take short-cuts in order to make the correct diagnosis for an appropriate treatment. A decision based on analysing one or a few ECG leads on a monitor screen or rhythm strip is a short-cut and may lead to incorrect interventions, some with potentially fatal consequences. A prerequisite is a 12-lead ECG. This allows one to answer the 2 most important questions in a tachycardia:

1. Is the rhythm regular or irregular?
2. Are the QRS complexes narrow (i.e. $\leq 100\text{ms}$ or $2\frac{1}{2}$ small blocks on the ECG paper) or wide?

Those who looked at the monitor screen made the initial assessment that this was a narrow QRS complex and therefore supraventricular tachycardia, possibly sinus tachycardia. As the patient was also hypotensive, it was thought the patient was hypovolaemic and a fluid challenge given. This had no effect and was incorrect. Next, because the tachycardia could have represented a more serious situation, a half-hearted electrical cardioversion with 50J was attempted but failed.

The 12-lead ECG shows a tachycardia of 162bpm (6x27) with:

1. Wide QRS complexes: one needs to look at all 12-leads to find the widest QRS: in VI the QRS is $3\frac{1}{2}$ blocks wide or 140ms. It is important to note that if one happened to see only lead III or aVF, as could happen on a bedside monitor, one could easily be mistaken that the QRS is narrow.
2. Regular rhythm: careful observation shows that the rhythm is absolutely regular. This is except for 3 fractionally earlier

beats which also happen to be narrower, seen best in the VI rhythm strip at the bottom of the 12-lead ECG (Figure 1). Note also that if one was again limited to only lead III or aVF, these slight changes in regularity and QRS width and morphology would easily be missed and an important observation confirming the diagnosis lost.

This combination of wide and regular QRS tachycardia, very simply and rapidly obtained, gives a 90% confident default diagnosis of ventricular tachycardia (VT). Knowledge that the patient has previously had a myocardial infarction strengthens the bet to almost 95%.

Any further analysis is just to deal with the remaining 5-10% of this tachycardia being something else:

- Ventricular pacing
- Atrioventricular re-entry tachycardia with ante-grade conduction down an accessory pathway
- A supraventricular tachycardia (SVT) that is conducted with right bundle branch block (RBBB) or left bundle branch block (LBBB) – but this will be with typical right or left bundle branch block morphology.

These differential diagnoses were easily excluded in this patient: He was not being paced. His pre-op ECG showed no evidence of an accessory pathway or Wolff Parkinson White pattern. The appearance of the QRS complexes, although superficially resembling right bundle block because of the predominantly positive QRS in VI, is not typical of real RBBB. Comparison to a

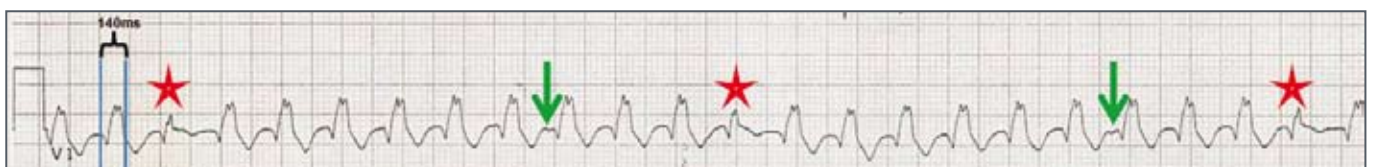

FIGURE 1: VI rhythm strip from 12-lead ECG

Note the width of the QRS = $3\frac{1}{2}$ little blocks = 140ms. Stars mark "fused / partial capture" beats. Arrows mark the small deflections caused by dissociated atrial activity.

typical RBBB (see Figure 2) shows that in V1 no sharp rapid initial R wave is seen and in V6, which in true RBBB has shallow slurred S waves, here the S waves are deeper than the height of the R waves. Since this RBBB-like pattern is not typical RBBB, this tachycardia is not SVT with aberration; again pointing to this being VT.

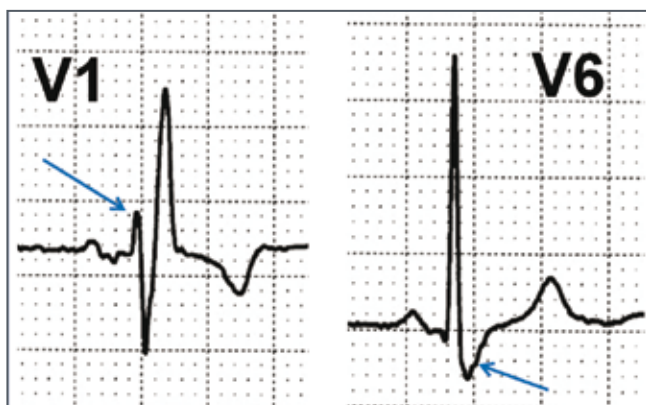


FIGURE 2: Typical right bundle branch block
Note the sharp, rapid, low amplitude R wave in V1. In V6, there is a shallow, slurred S wave.

Even further strengthening of the case to 100% certainty of this being VT is possible by 2 other observations:

- The occasional slight change in regularity and narrowing of the QRS complexes. These beats represent fusion or partial capture beats in which the ventricular complex is the result of 2 near-simultaneous depolarisations: i) From the VT superimposed on or fusing with ii) depolarization of the ventricles via the conduction system of an impulse that arose from the atria. This shows that the atrial rhythm must be dissociated and not the driver of the ventricular rhythm, confirming VT.
- Little indentations are noted in at least 3 places in or at the end of the T waves in V2 and V1. This is just more evidence of dissociated atrial activity.

Please note that the diagnosis and 90% certainty of VT did not require the search for this atrial activity which more often than

not cannot be found. However, if it can, then the diagnosis is certain.

Having made the diagnosis of VT, what is the treatment?

The correct answer is (c): electrical cardioversion. However, this must be done properly: correctly placed paddles/patches and with adequate energy. In an adult, I wouldn't waste time with 50J as this may not only fail but actually be pro-arrhythmic and induce Ventricular Fibrillation. It is recommended that one should start with 150J if using a biphasic defibrillator or 300J with the old-fashioned monophasic systems. Since we are absolutely certain of our diagnosis, if the first shock does not work, we should give another.

What about IV amiodarone?

This is not first-line therapy. Amiodarone has a cardioversion of VT success rate of only about 25%. It is good at keeping a patient out of VT but not good at stopping the VT. Furthermore, it does not come without some risk; it drops the blood pressure and cardiac perfusion pressure which must be avoided in post CABG patients and can convert a VT patient with relatively stable haemodynamics into an unstable emergency.

Adenosine should never be given if the diagnosis of VT is made or just to test and see if the tachycardia could be an SVT with aberration. Firstly, adenosine will not terminate the VT and secondly, it may be pro-arrhythmic and may again destabilize the situation.

CONCLUSIONS / LESSONS

- To make the correct diagnosis of a tachycardia, a 12-lead ECG is essential.
- All tachycardias must be analysed for regularity and QRS width.
- If the tachycardia is regular and wide, the default diagnosis is ventricular tachycardia.
- Electrical cardioversion is the first line of treatment in VT but it must be done properly and with adequate energy.