

Systematic analysis of the ECG (recorded at standard speed of 25mm/s and 10mm/mV) reveals the following important observations:

- Regular rhythm with ventricular rate of 102bpm with some recurring variations probably related to respiration.
- Atrial rhythm with P-axis of approximately 45°, i.e. within the normal range for sinus origin (15-75°). Hence a sinus tachycardia.
- Abnormal P-waves (Figure 1):
 - Prolonged duration: 140ms (3½ blocks). (Normal is <120ms.)
 - Prominent notch in Lead II (and others). The duration between the peaks of the bifid P is 70ms (1¾ blocks). (Normal maximum between bifid peaks <40ms.)
 - In Lead II the P is < 2.5mm tall (0.25mV); normal.
 - In Lead VI (Figure 2) the P has a prominent negative component which is:
 - Bigger than the positive component;
 - Deeper than 1mm; and
 - Prolonged.
- PR interval = 200ms (upper limit of normal).
- QRS duration = 100ms (half a big block) (upper limit of normal).
- QRS-axis is almost +120° i.e. right axis deviation. (Normal in adult +90 to -30°.)
- QRS size and morphology are abnormal:
 - In Lead VI there is a Rs pattern (i.e. dominant R-wave, or R>s) with a R which at maximum measures 6mm (0.6mV). (Normal is variably reported as < 5 or 7mm.)

- Prominent S-waves in Leads V2-V6.
 - Sum of R in VI and S in V5 or V6 = 11mm. (Normal is up to 10mm.)
 - No pathological Q-waves are noted in the inferior leads, chest leads or high lateral leads.
 - Poor R-wave progression V2-V6.
8. T-waves flat or mildly inverted in VI with minor inversion V2-V4.

In summary, there are atrial abnormalities and the QRS is dominantly positive in VI and has right axis deviation.

Atrial abnormality

The term atrial abnormality, although seemingly less specific, is preferred to terms such as atrial hypertrophy, atrial enlargement, atrial overload, atrial strain and atrial conduction defect because several of these factors that affect the P-waves often appear in combination and may not be distinguishable.

The observations listed above are typical of left atrial abnormality which is characterised by a prolonged total atrial activation time representing asynchrony of right and left atrial activation. This occurs either because the left atrium is so enlarged that it takes much longer to depolarize than the right atrium or there may be a conduction disturbance in the atrial wall or from right to left atrium as when Bachman's bundle, the specialised electrical connection between the atria, is affected.

Occasionally there may be biatrial abnormality. Here one would look for concomitant right atrial abnormality: tall P in Lead II

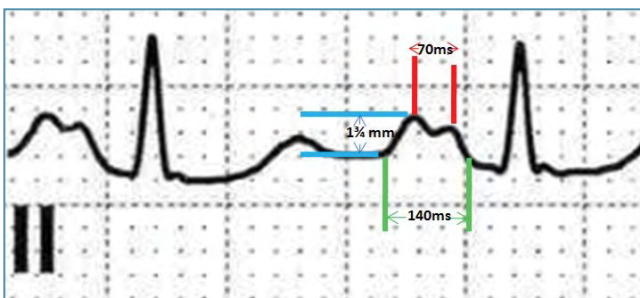


FIGURE 1: Left Atrial Abnormality in Lead II
The P wave in Lead II is abnormally wide (140ms) and notched. (Normal is <120ms). There is a 70ms duration between the bifid-P peaks. The P wave amplitude of 1.75mm (0.175mV) is normal. If it had been >2.5mm, additional right atrial abnormality, and biatrial abnormality would have been diagnosed.

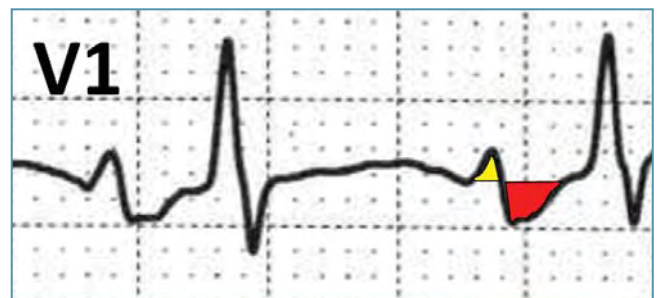


FIGURE 2: Left Atrial Abnormality in Lead V1
The P wave has a prominent negative component (red) which is larger than the positive component (yellow) and deeper than 1mm. The whole P wave with its positive and negative components is longer than normal.

(>2.5mm) and prominent in V1 and V2 (>1.5mm) without primarily affecting the P-wave duration.

Dominant R in V1

It is worth reviewing the differential diagnosis of "Dominant R-wave" in V1 (i.e. R>S) because consideration of each of the diagnoses should lead one to look for additional confirmatory evidence, which if absent, may help to exclude it. The list includes:

- It may be normal in babies and the very young.
- A true posterior infarction, but usually the T-wave is upright in V1, the QRS-axis is not right, and there is evidence of inferior myocardial infarction.
- Right bundle branch block (with a small r followed by a tall R prime) or other intraventricular conduction abnormality with left septal fascicular block. The QRS would be wide.
- Wolff Parkinson White (WPW) pattern due to an accessory pathway, often left-sided. The observation would be accompanied by "delta" waves of WPW and short PR interval.
- Rare causes include Duchennes' muscular dystrophy.
- Also rarely, it may be due to displacement of the heart due to pulmonary disease (e.g. massive right pneumothorax or effusion). The T-wave in V1 is typically upright.
- Right ventricular hypertrophy (RVH). Generally, the criteria for RVH have low sensitivity and specificity. The diagnosis is significantly supported by additional findings: R in V1 >0.7mv, S in V1 <0.2mv, qR pattern in V1, right axis deviation of >110° and secondary T-inversion in the right chest leads. (The term of secondary ST-T abnormality is preferred to "strain".) No single criterion can be recommended. Combination calculations e.g. sum of R in V1 and S in V5 or V6 >1.05mv may give false positives.

Right Axis Deviation (i.e. > 90°) must always make one consider the following differential:

- RVH.
- Normal in young slender person.
- Chronic obstructive airways disease (COAD) without cor pulmonale and RVH.
- Lateral myocardial infarction (with evidence of lateral Q-waves).

- Left posterior fascicular block or hemi-block (LPHB). It is important to note that it may not be possible to differentiate abnormal right axis deviation due to RVH from that secondary to LPHB without clinical information or clinical examination such as parasternal RV impulse, raised JVP or loud P2.

Thus, the ECG diagnosis in this patient is "Sinus tachycardia with left atrial abnormality and right ventricular hypertrophy".

Clinical Diagnosis

The ECG diagnostic combination fits best with answer "D", mitral stenosis. This patient had severe stenosis with a mitral valve area of 1.0cm² and secondary pulmonary hypertension (systolic of 65mmHg) with RVH.

The marked left atrial abnormality observed in this ECG is not in keeping with Tetralogy of Fallot, chronic pulmonary thromboembolic disease and ASD. The latter, if of the "primum" type, is also associated with left axis deviation, not right. Dextrocardia could have been considered based strictly on the QRSs alone: right axis and poor R-wave progression; but the diagnosis can be discarded immediately by the normal P-wave axis.

Conclusions / Lessons

- Systematic analysis and interpretation of the ECG enhances the clinical assessment of the patient.
- Left (or right) atrial abnormality is the preferred term.
- Right ventricular hypertrophy can be diagnosed by a variety of ECG signs which individually may be non-specific but are useful as a constellation.
- Right axis deviation in isolation cannot be interpreted as due to RVH or LPHB without clinical input.

References

1. Hancock EW, Deal BJ, Mirvis DM et al. AHA/ACCF/HRS Recommendations for the standardisation and interpretation of the electrocardiogram. JACC 2009; 53: 992-1002
2. Okreglicki A, Scott Millar R. ECG: PQRST morphology – clues and tips. SA Heart Journal 2006;3:27-36.
3. Chou's Electrocardiography in Clinical Practice. Ed. Surawicz B, Knilans T. 6th edition. Saunders Elsevier.