

### Systematic analysis of the ECG shows:

1. **Rate and rhythm:** regular with a conducted rhythm and a ventricular rate of 48 bpm i.e. bradycardia.
2. **Atrial activity:** clear P-waves are noted preceding each QRS complex. These P-waves are normal in morphology, duration (<2.5 little blocks) and axis (approximately 60°) i.e. compatible with normal sinus node origin. The PR interval is long (280ms).
3. **The QRS is abnormal:**
  - a. QRS width: 150ms (3¾ blocks x 40ms per block).
  - b. QRS axis: this is quite difficult; superficially it is around 0° but analysis of vectors and the areas, not the amplitudes, of the individual deflection components of the QRS complex on either side of the isoelectric baseline suggests possible right axis.
  - c. QRS morphology: pathological Q-waves (i.e. ≥40ms or a small block and deeper than 1/3 of R) are present in Leads II, III, aVF and probably in V6. There is a small non-pathological Q-wave in V1 which is allowed. In the right chest leads, particularly V1 and V2, there are dominantly positive QRS complexes with a double R (R R'). There are poor R-waves in V3-V6. In the lateral chest leads and especially Leads I and aVL, the QRS complexes terminate with wide and not very deep S-waves. This combination of findings in the right and lateral leads is best explained by right bundle branch block (RBBB).
4. **ST segment** elevation in the inferior leads and in the left chest leads together with tall quite symmetrical T-waves is due to myocardial ischaemia. Pathological Q-waves in these leads are evidence of evolved myocardial infarction. The ST segment elevation in Lead III is higher than in Lead II; also the frontal plane axis of the ST segment is deviated to the right, in the south-east quadrant. These observations suggest that the inferior infarction is more likely to be due to occlusion of the right coronary artery than of the circumflex artery.
5. **T-waves:** upright or positive in the right chest leads and negative in the lateral leads, I and II. This additional observation that the

T-waves do not follow the usual orientation in RBBB of being opposite to the terminal part of the QRS confirms that the T-wave changes are not merely secondary to the conduction abnormality of BBB but reflect other pathology viz. ischaemia.

In summary, so far, we have established evidence of acute infero-lateral myocardial infarction and RBBB.

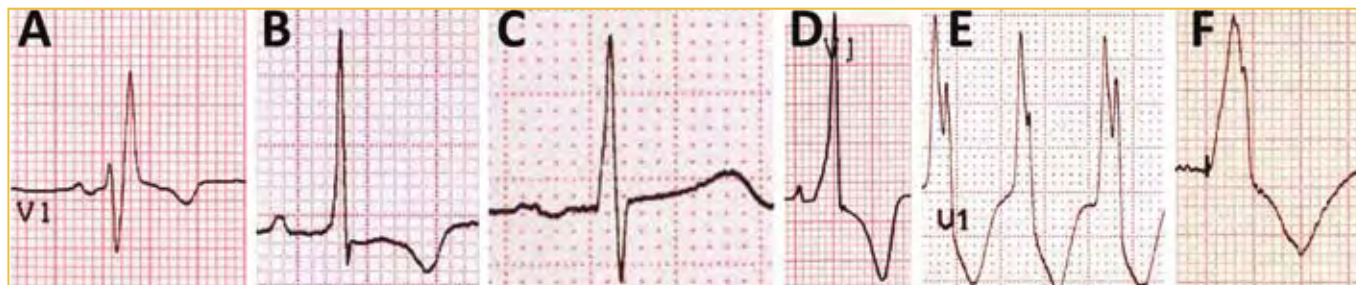It is important to observe that the QRS complexes show conduction velocities in the ventricles typical of BBB with an initial short rapid component due to conduction of the normally functioning bundle. The QRS complexes end with a wide component due to slow conduction because of failure of rapid conduction due to the BBB.

Appreciation of this abnormality late in the QRS helps exclude the pathologies that may also give a dominant positive QRS complex in V1 and 2: in posterior infarction, the initial dominant positive complex would be wider and followed by the usual S-wave typical of these leads; RV hypertrophy would not have a delayed positive component (Figure 1). Also, the apparent waves seen at the J-point or junction point between the QRS and the ST segment in Leads III and aVF are clearly part of the wide QRS when tracked to the simultaneously recorded QRSs in the other leads on the ECG. Thus, these are not the J-waves of hypothermia which are typically seen after the end of, and not within, a narrow QRS complex and usually in the left chest leads.

Despite this not being hypothermia, the bradycardia remains intriguing. This patient has a significant myocardial infarction, hypotension and mild cardiac failure, yet she is going slowly.

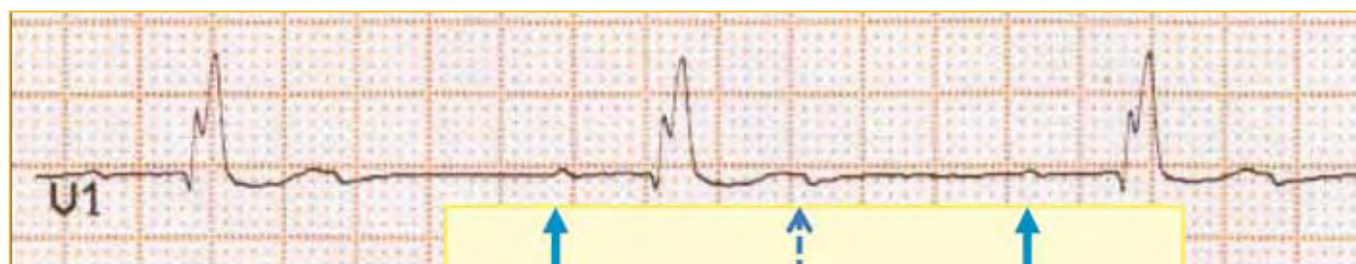
It is well recognised that in inferior infarction there can be associated bradycardiac rhythm disturbances, the causes of which may be:

- Sinus bradycardia due to ischaemia of the sinus node;
- Sinus arrest;
- Vagal effects mediated by neurocardiogenic mechanisms, irritated/ischaemic C-fibres in the inferior ventricular wall and the Bezold-Jarisch reflex;



**FIGURE 1: Differential Diagnosis of Dominant R in V1**

- A. Right Bundle Branch Block (RBBB) dominantly positive in V1. Note the normal initial R-wave followed by the tall and wide R-wave.
- B. Right ventricular hypertrophy causing dominant R in V1.
- C. Posterior infarct with its mirror-image Q-wave visible as a dominant R in V1. Note this R-wave, like a pathological Q-wave is wider than 40 ms. (Compare to B).
- D. WPW due to a left lateral accessory pathway presenting as a dominantly positive QRS complex in V1. Note the short PR of 90 ms, the slurred onset of the QRS and its rapid termination.
- E. Ventricular tachycardia with a RBBB-like morphology in V1 and dominantly positive QRS.
- F. Pacing in the left ventricle giving a pseudo-RBBB morphology and positive QRS in V1. Note the tiny pacing spike at the onset of the ventricular complex.



**FIGURE 2: Detection of Sinus Rhythm with 2:1 AV conduction**

The V1 rhythm strip from ECG no.19 shows clear P-waves which are marked on the piece of paper alongside. Exactly half way between these 2 marks the dashed arrow points to the small consistent deflection at the end of the T-wave and indicates the other P-waves that are not conducted.

- AV node dysfunction due to ischaemia because of involvement of the AV nodal artery; or
- Functional AV node blocks of varying degree variably attributed to, amongst others, local adenosine release.

However, before attributing the observation of a slow ventricular rate to a combination vagal effect on the sinus node giving sinus bradycardia and on the AV node giving 1° AV block, it is important to carefully scrutinize the ECG to ensure that one is not missing a faster atrial or sinus rhythm that would be more appropriate to the

clinical scenario of hypotension and cardiac failure and a masked AV conduction abnormality accounting for the slow ventricular rate.

Armed with suspicion of possible P-waves other than those that conduct down to the QRS, one should account for every unusual bump or notch. In 2 different leads, I and V1, there are unusual deflections related to the T-waves. In V1, at the end of the T-wave there is a slight positive before a small sharp negative deflection. In Lead I, at the end of the T-wave there is a positive hump. Could these be P-waves superimposed on the T-waves?

**ECG and QUESTION** on page 124

**There are two ways to prove this:**

1. If it can be shown that this deflection falls midway between two P-waves that conduct to V, this would be supportive that the atrial rate is actually double the ventricular rate i.e. 96 bpm and there is 2:1 AV conduction block. (This is best shown by taking a piece of paper, making a mark on it opposite a P-wave that conducts to the QRS and another mark against a similar P-wave. A line made exactly half way between these 2 marks does, in fact, coincide with the little deflection noted at the end of the T-waves) (Figure 2).
2. Prolonged recording that may show higher degrees of block and expose the additional P-waves "uncontaminated" by the T-waves. This is exactly what was seen on the bedside ECG monitor (Figure 3).

This confirms that the correct ECG diagnosis is d) sinus rhythm with second degree AV block, bundle branch block and infarction.

**The significance of this finding:**

1. This second degree AV block cannot be classified as either Mobitz Type 1 or Type 2. Only the descriptive term "second degree with 2 to 1 conduction" can be used.
2. The site of this block may be in the AV node or below, in the conduction system. The RBBB is evidence of conduction system disease. The prolonged PR interval in the setting of a normal sinus rate (96 bpm), signifying no increased vagal tone effect on

the AV node, suggests that there is abnormally slow conduction down the functioning left bundle branch.

3. With this interpretation of probable bilateral, right and left bundle branch, conduction abnormality, there is a high risk of complete heart block in the post myocardial infarction period. Since the block is likely not to be high i.e. in the AV node but low in the conduction system, there may be no ventricular escape rhythm if complete AV block occurs. Therefore pacing is indicated. In this patient, a temporary prophylactic pacemaker was placed. A few hours later she did, in fact, progress to complete heart block with no escape rhythm and there was relief that she had a pacing backup. Unfortunately, the pacing lead dislodged the next day with resulting asystole. Despite prompt resuscitation and external pacing, which did not reliably capture to pace the heart, the patient died on transfer to the cath lab for repositioning of the pacing wire.

**CONCLUSIONS / LESSONS**

- In any bradycardia, especially in the peri-infarct setting, always suspect that the atrial rate could be faster. Look for non-conducted P-waves and consider AV block.
- Evidence of extensive conduction system disease in the post-infarct setting is an indication for backup/prophylactic ventricular pacing.



**FIGURE 3: Bedside monitor ECG strip with intermittent high degree AV block**

Continuous monitoring revealed AV block of higher degree than 2nd degree with 2:1. The solid arrows point to the visible P-waves and the dashed arrows line up with P-waves that are obscured by the T-waves. The arrowed segment shows: 2:1, 4:1, 2:1, 3:1 AV conduction.