

# Image in cardiology

## Haemodynamics in a nutshell

**W. Lubbe, P.G. Herbst and A.F. Doubell**

Division of Cardiology, Department of Medicine, Faculty of Health Sciences, University of Stellenbosch, Tygerberg, South Africa

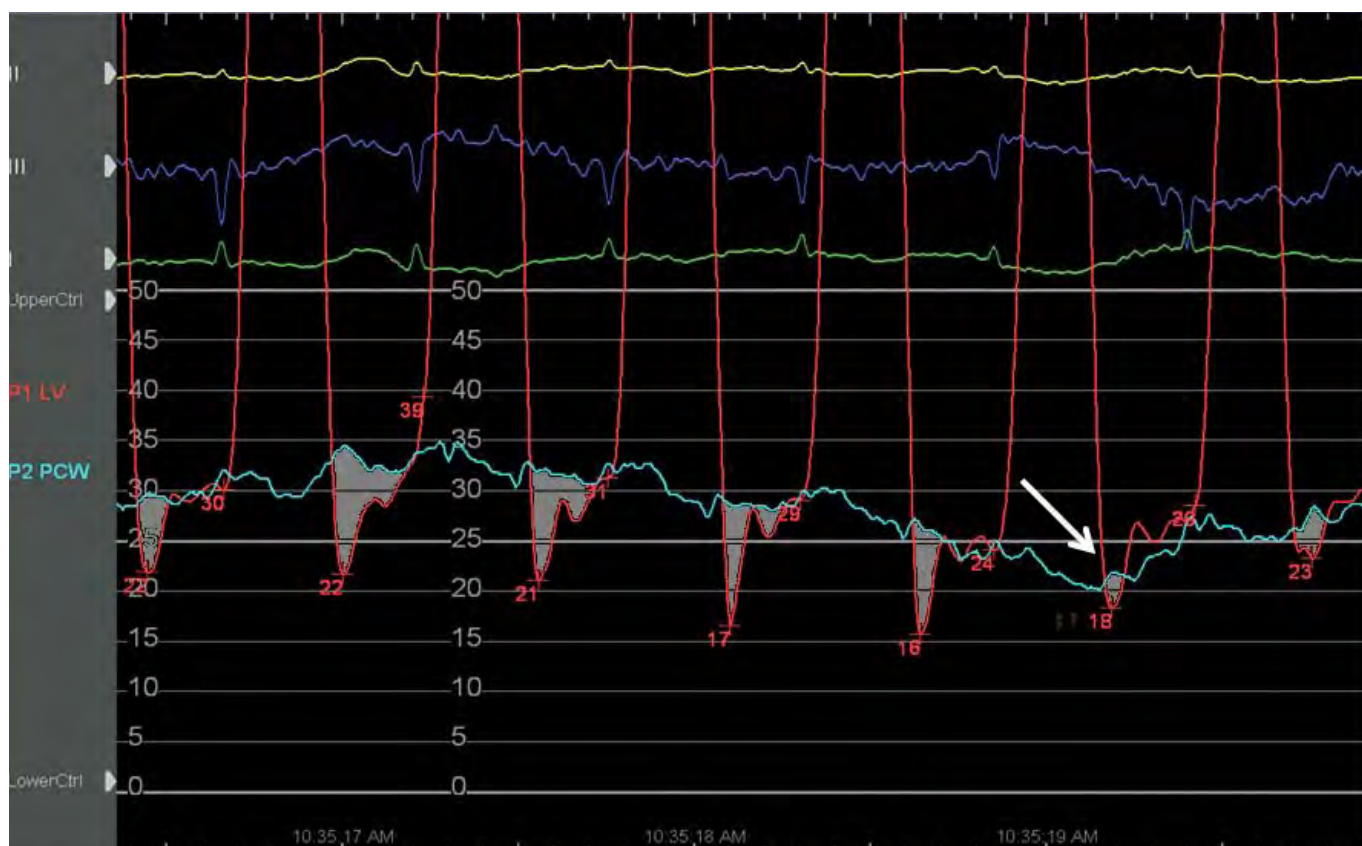
**Address for correspondence:**

Dr Wayne Lubbe  
Division of Cardiology  
University of Stellenbosch  
PO Box 19063  
Tygerberg  
7505  
South Africa

**Email:**

wwlubbe@gmail.com

A 41-year-old male presented with predominantly right heart failure symptoms due to suspected constrictive pericarditis (CP). The physical examination revealed an elevated jugular venous pressure, ascites and hepatomegaly. A pericardial knock was absent but pulsus paradoxus of 12mmHg was present. The ECG demonstrated low QRS voltages and isolated repolarisation abnormalities and a penetrated lateral chest radiograph did not show calcification. The pericardium did not appear thickened on a transthoracic echocardiogram but bi-atrial dilatation, septal shift with respiration and septal bounce were present. The IVC was dilated with no respiratory collapse. Doppler echocardiography demonstrated varying transmitral inflow velocities with respiration and an increased medial mitral annular velocity ( $e'$ ) of 15cm/s compatible with CP. The patient underwent cardiac catheterisation prior to presentation to cardiothoracic surgery.



**FIGURE 1:** Left ventricular (LV) and pulmonary artery wedge (PCW) pressures obtained during respiration. The shaded area represents the pressure gradient into the LV and is shown to decrease significantly during inspiration signifying dissociation of intrathoracic and intracardiac pressures (arrow).

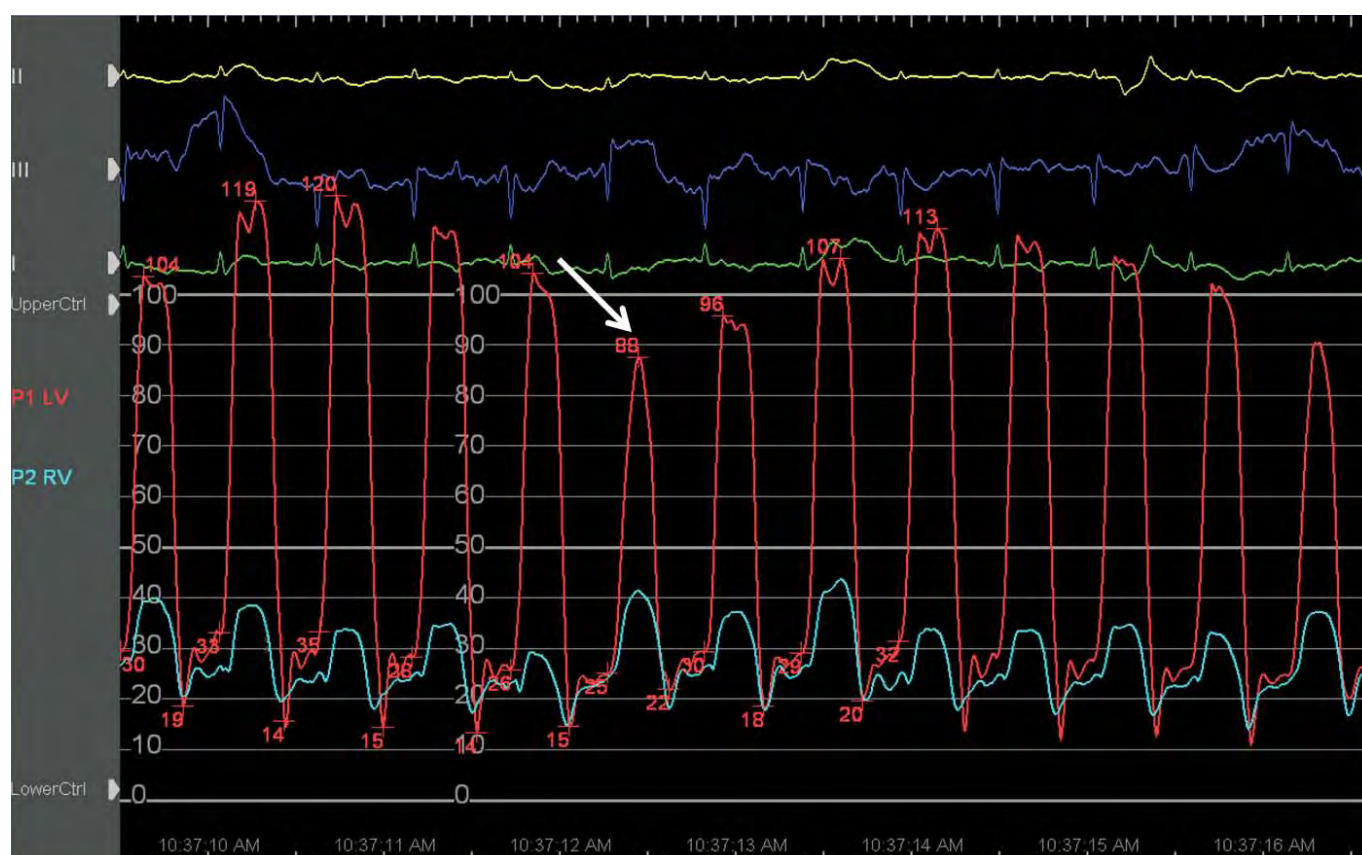
The two central pathophysiological features that differentiate CP from other causes of restrictive ventricular filling are dissociation of intrathoracic and intracardiac pressures and enhanced ventricular interaction.<sup>(1,2)</sup> In the heart with a normal pericardium, inspiration causes a decrease in intrathoracic pressure, which is matched by a similar pressure drop in the left ventricular (LV) cavity, thereby maintaining flow into this cavity during the respiratory cycle. In the case of CP where a thickened, non-distendable peel encases the heart, there is a lack of transmission of respiratory intrathoracic pressure change to the cardiac chambers. This means that during inspiration the drop in intrathoracic pressure is not transmitted to the LV cavity thereby decreasing the flow gradient into this chamber. This dissociation of intrathoracic and intracardiac pressures seen during respiration affects the rate of filling of the LV relative to the right ventricle (RV). The total cardiac volume remains unchanged within the rigid pericardium and because of the varying LV filling rate during the respiratory cycle the interventricular septum shifts into the LV in inspiration and into the RV during expiration, thereby determining the difference in end diastolic volumes in the two ventricles. Demonstration of this enhanced ventricular interaction within the fixed volume of the rigid peri-

cardium is the most useful information obtainable by cardiac catheterisation in the diagnosis of CP with a reported sensitivity of 97% and a predictive accuracy of 100%.<sup>(3)</sup>

The 2 figures represent the cardiac catheterisation data of the above patient. Dissociation of intrathoracic and intracardiac pressures was demonstrated by analysing the left ventricular and pulmonary artery wedge pressures obtained during respiration (Figure 1). Enhanced ventricular interaction was demonstrated by simultaneous LV and RV pressure acquisition reflecting discordance of the left and right ventricular pressures (Figure 2).

## REFERENCES

1. Hurrell DG, Nishimura RA, Higano ST, et al. Value of dynamic respiratory changes in left and right ventricular pressures for the diagnosis of constrictive pericarditis. *Circulation* 1996;93:2007-13.
2. Nishimura RA. Constrictive pericarditis in the modern era: a diagnostic dilemma. *Heart* 2001;86:619-23.
3. Talreja DR, Nishimura RA, Oh JK, et al. Constrictive pericarditis in the modern era: novel criteria for diagnosis in the cardiac catheterisation laboratory. *J Am Coll Cardiol* 2008;51:315-9.



**FIGURE 2:** Pressures in the left (LV) and right ventricle (RV) obtained during exaggerated respiration. At peak inspiration (arrow), there is a decrease in LV pressure and a concomitant increase in RV pressure, indicating discordance of ventricular pressures.