

The surgeon's role in transcatheter aortic valve implantation (TAVI)

Arnaud Van Linden, Johannes Blumenstein, Thomas Walther and Joerg Kempfert

Department of Cardiac Surgery, Kerckhoff Klinik Bad Nauheim, Germany

Address for correspondence:

Prof Dr Thomas Walther
Kerckhoff-Klinik Bad Nauheim
Benekestrasse 2-8,
61231 Bad Nauheim
Germany

Email:

t.walther@kerckhoff-klinik.de

INTRODUCTION

Aortic stenosis (AS) is the most common acquired heart valve disease in the Western world, which stays asymptomatic for a long time, but with rapid progression once it becomes symptomatic. The one-year mortality for medical treatment varies around 50% after first symptoms appear in patients with severe aortic stenosis.^(1,2) The gold standard for the treatment of patients suffering from severe symptomatic AS is conventional surgical aortic valve replacement (AVR), which improves both symptoms and survival. The conventional AVR via sternotomy and using cardio pulmonary bypass is a routine procedure in cardiac surgery with very good results.⁽³⁾ Some new developments, such as minimally invasive approaches to the aortic valve using a partial upper sternotomy or parasternal intercostal incision and new generation tissue valves have improved the results after conventional AVR.^(4,5)

An increase in average life expectancy results in an increasing number of elderly patients with severe AS. The patient's age alone is not an independent risk factor for conventional AVR and it can still be performed in octogenarians with a 30-day mortality around 5-10%. Therefore, isolated advanced age should not be seen as a contra-indication for conventional AVR.⁽⁶⁻⁸⁾

Despite the good results for conventional AVR, there are still at least one third of elderly patients with severe AS who are not referred for cardiac surgery due to the fact that their referring

ABSTRACT

Transcatheter aortic valve implantation (TAVI) has evolved into a routine procedure for elderly high-risk patients with severe aortic stenosis in specialised centres. It can be performed via a transfemoral or a transapical approach. Both approaches are truly minimally invasive and avoid the use of cardio-pulmonary bypass and cardioplegic arrest. TAVI is associated with good outcome and acceptable complication rates. The outcome of TAVI has improved over the last few years as centres became more experienced in the procedure. Up to now there is no clear evidence-based benefit for one or the other approach. A careful patient selection for each approach is therefore crucial for good results. Both procedures should be performed by a heart team of cardiologists, cardiac surgeons and cardiac anaesthetists. The knowledge the cardiac surgeons gained over the last decades by treating aortic stenosis with conventional aortic valve replacement is very important in TAVI procedures: Not only in terms of the procedure itself, but also for pre-operative patient screening. TAVI must be approached as a team effort where cardiologists and cardiac surgeons play an equal role and should not be performed without a cardiac surgeon.

SAHeart 2012; 9:32-38

cardiologists assumed the surgical risk as too high.^(9,10) This summation is usually based on the existence of co-morbidities such as low left ventricular ejection fraction, pulmonary disease or previous cardiac surgery. From a surgeon's point of view, the assessment of surgical risk is not always appropriate and many of these patients are still good candidates for conventional AVR. But there is a defined group of patients with a remarkably higher risk profile where conventional AVR with the use of cardio-pulmonary bypass and cardioplegic arrest should be avoided. For this subgroup of patients at high risk, transcatheter aortic valve implantation (TAVI) is a truly minimally invasive alternative treatment option that avoids cardio-pulmonary bypass, sternotomy and cardioplegic arrest.

THE DEVELOPMENT OF TRANSCATHETER AORTIC VALVE IMPLANTATION

The first successful transcatheter aortic valve implantation was performed by Alain Cribier and his team in a patient with severe

aortic stenosis at high surgical risk in 2002.⁽¹¹⁾ With this approach it was possible to implant an aortic bioprosthesis fixed on a stent within the native stenotic aortic valve, starting with an antegrade transseptal approach. The transseptal approach was associated with different complications and potential risks such as pericardial tamponade, mitral valve incompetence and haemodynamic instabilities leading to acute procedural mortality.⁽¹²⁾ These potential complications led to the introduction of the retrograde transfemoral approach.⁽¹²⁾

Limitations of the initial experience with the transfemoral approach were the sheath diameters of 22 - 24 French. These large sheath diameters led to major vascular complications in some cases, especially because the high risk TAVI patients often have calcified femoral vessels. The incidence of serious vascular complications after transfemoral approach including retroperitoneal haematoma, femoral artery dissection, aneurysms and major bleeding varies between 10 and 16%.^(1,17) The current sheath sizes are reduced to 18 French and a new expandable sheath with a 16 French diameter (eSheath™, Edwards Lifesciences) has been introduced. The smaller sheath diameters may reduce the incidence of major vascular complications. Furthermore calcification often extends up to the aortic arch, which has to be crossed by the transfemoral devices. This led to a stroke rate of up to 10%.⁽¹³⁾ Some cardiac surgeons realised that an alternative surgical approach for TAVI avoiding the major complications of the transfemoral approach was necessary. Initial animal studies were performed and the feasibility of the antegrade transapical access was proven.⁽¹⁴⁾ The first minimally invasive transapical aortic valve implantations (TA-AVI) in selected high-risk patients were performed in 2006.^(15,16)

INDICATION FOR TAVI

Until now there have been no stringent guidelines for TAVI indication. A position statement from the European Association of Cardio-Thoracic Surgery (EACTS) and the European Society of Cardiology (ESC), in collaboration with the European Association of Percutaneous Cardiovascular Interventions (EAPCI) offers some recommendations for potential TAVI patients.⁽¹⁷⁾ In summary TAVI should be reserved for high risk patients presenting with a logistic EuroSCORE >20% and/or STS-score >10%. TAVI might also be a treatment option for patients with risk factors that are not represented in both of the scores such as porcelain aorta,⁽¹⁸⁾ patent

bypass grafts and patients with liver cirrhosis. After introducing the so-called valve-in-valve TAVI it is also possible to implant a transcatheter valve inside a degenerated xenograft.⁽¹⁹⁻²¹⁾

Besides the high-risk profile, patients who should undergo TAVI need to fulfil some anatomical criteria. In Europe 2 different types of TAVI valves are commercially available: The Medtronic CoreValve® for retrograde transfemoral (or transsubclavian/trans-aortic) access only and the Edwards SAPIEN™ which can be implanted transfemorally or transapically. Both TAVI devices are available in limited prosthesis sizes and their sheaths for the transfemoral access are at least 18 French. Therefore pre-operative imaging including transoesophageal echocardiography (TEE) and computed tomography (CT) is very important to evaluate and measure the patient's anatomical conditions including aortic valve anatomy, femoral artery diameter and distance of the coronary ostia to the aortic annulus. The diameter of the native aortic annulus should be between 18mm and 28mm (Figure 1), the femoral vessels should have a diameter of at least 6mm for the transfemoral approach and the distance between the aortic annulus and the coronary ostia should be at least 10mm to avoid an occlusion of the coronaries (Figure 2).

Certainly, a too large or a too small annulus diameter, as well as too short distance between the aortic annulus and the coronary ostia are contra-indications for TAVI as it is technically impossible or high risk to perform the procedure. In the initial TAVI experience a native bicuspid aortic valve was viewed as a contra-indication, but subsequently some successful TAVI procedures have been performed in patients with a bicuspid aortic valve.^(22,23)

VALVE TYPES

There are 2 different types of TAVI valves commercially available in Europe:

- The Medtronic CoreValve® is a self-expandable porcine pericardial valve on a nitinol stent. It is available in two sizes, a 26mm and a 29mm valve. The delivery system only allows for retrograde implantation. The CoreValve® has not obtained FDA approval yet, and
- The Edwards SAPIEN™ valve: A balloon-expandable bovine pericardium valve on a stainless-steel stent. The SAPIEN™

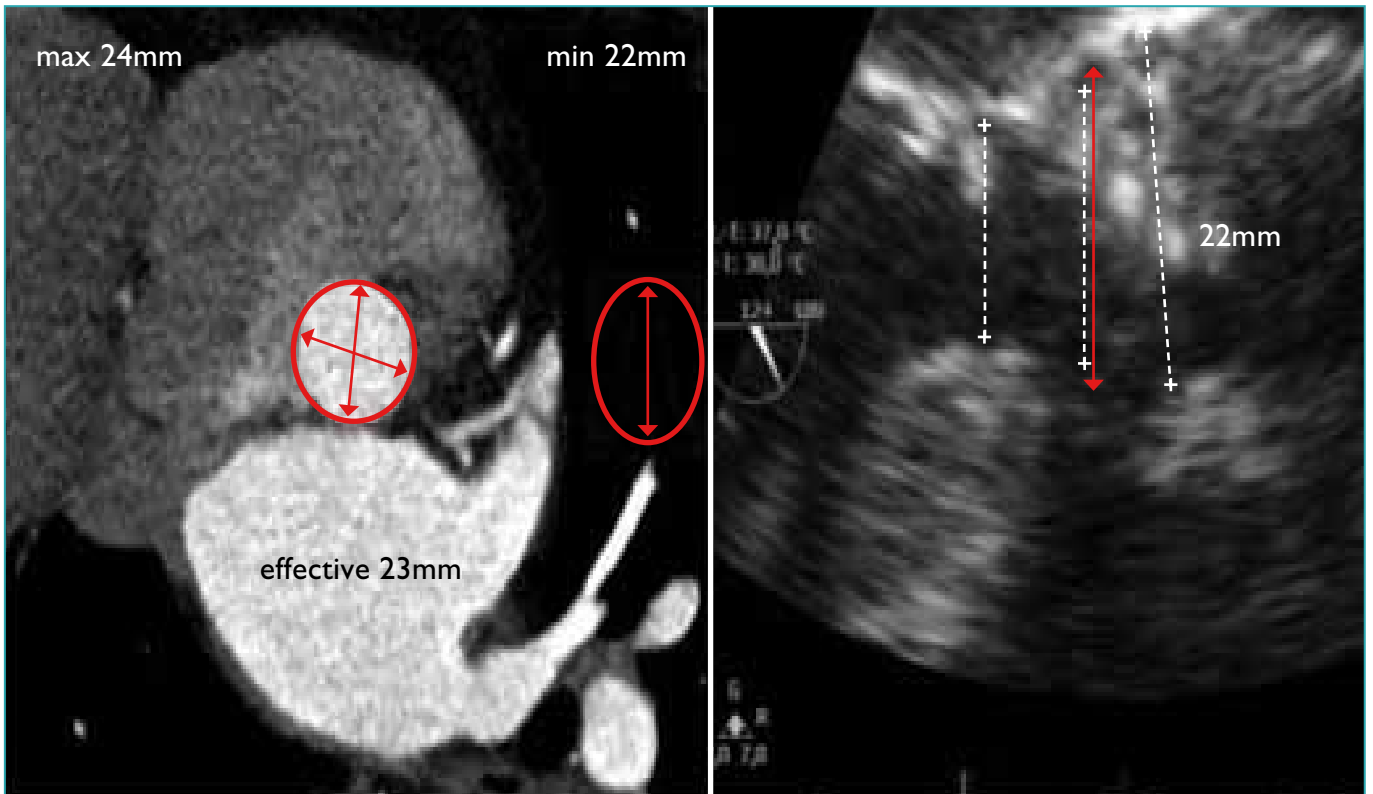


FIGURE 1: Measurement of the aortic annulus diameter using CT and TEE.

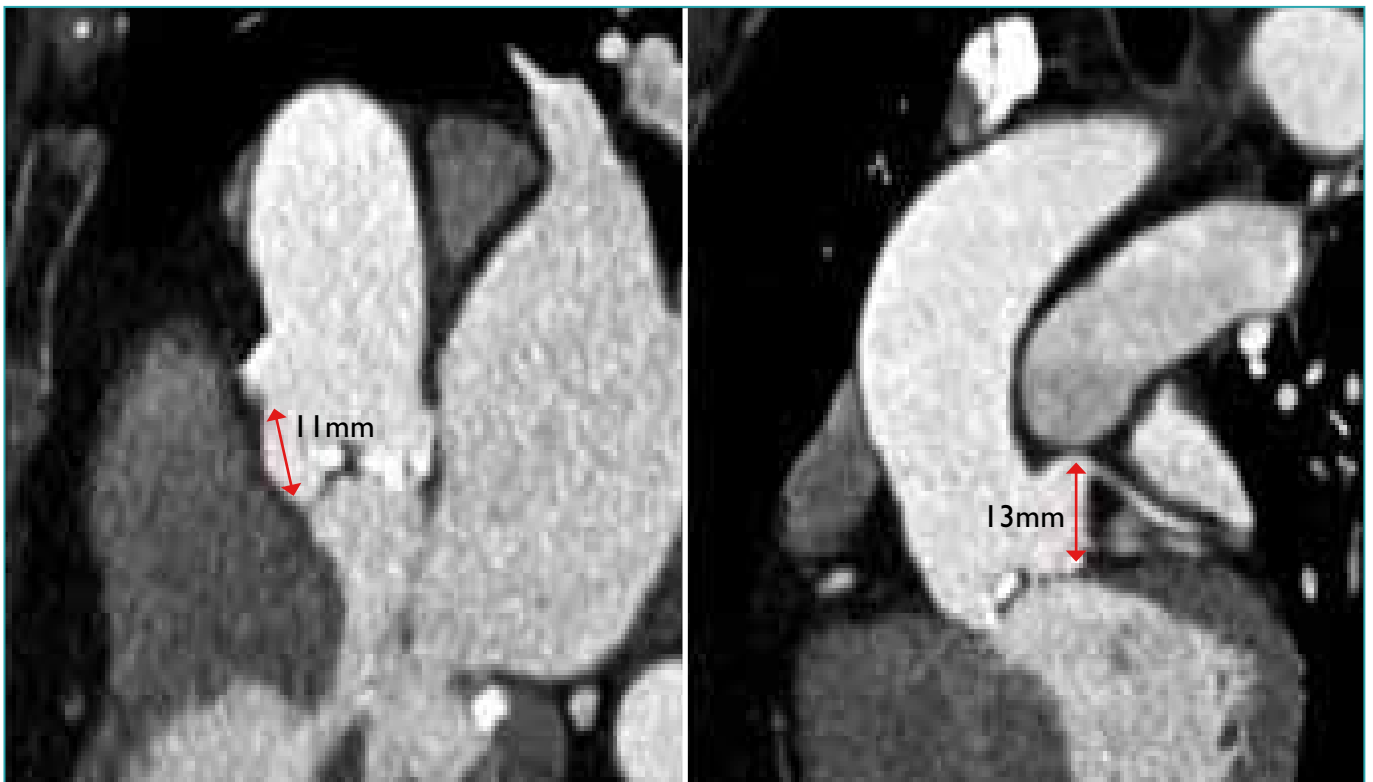


FIGURE 2: Measurement of the distance between the coronary ostia and the aortic valve annulus.

valve is available in a 23mm and 26mm prosthesis size and can be implanted either transfemorally or transapically. The new generation is the SAPIEN XT™ valve, which has some modifications in design (cobalt-chrome stent) and also offers a 29mm valve for the transapical approach. With the SAPIEN™ valve a large randomised trial for FDA approval has been completed recently^(1,24) and approval will probably be granted soon.

BASIC STEPS OF TAVI

Both approaches - the transfemoral (TF) and the transapical (TA) AVI - allow for minimally invasive off-pump aortic valve implantation. Right at the beginning of both approaches a venous back-up wire and an arterial sheath should be placed in the femoral vessels as a safety net, allowing for immediate conversion (femoral-femoral, percutaneous cannulation) to cardio-pulmonary bypass, in case of complications.⁽²⁵⁾

For TF-AVI both femoral arteries are punctured: One for the device implantation and the other for the pigtail catheter. After retrograde crossing of the native aortic valve a balloon valvuloplasty is performed under rapid ventricular pacing. After haemodynamic recovery the prepared valve on its device is introduced and positioned under fluoroscopic control. Once a good position is confirmed, the valve is deployed under a second brief episode of rapid ventricular pacing. After implantation the valve function is assessed by either fluoroscopy and/or by TEE. If any significant paravalvular leak is noticed it is possible to re-balloon the valve with a slightly larger balloon. After removing the delivery sheath, the femoral artery has to be closed either surgically or by using a closure device (for example Prostar XL™, Abbott Vascular Devices, Redwood City California).

Potential advantages of the TF approach are the avoidance of a mini-thoracotomy and that it can be performed without general anaesthesia. When using local anaesthesia it is not possible to use intra-operative TEE.

TA-AVI is performed through a 5cm left lateral mini-thoracotomy in the mid-clavicular line in the 5th or 6th intercostal space. After opening the pericardium, the apex is secured with 2 Teflon pledgetted purse-strings followed by apical puncture. Then, the native

aortic valve is crossed antegrade with a soft guide wire, which is changed to a super-stiff wire positioned down into the descending aorta. The femoral artery is punctured and through the sheath the pigtail catheter is positioned just above the aortic valve. This will act as a safety net for rapid CPB initiation if needed during the procedure.

The valvuloplasty balloon is now introduced through the apical guide wire and the valvuloplasty is performed under rapid ventricular pacing. Again, after haemodynamic recovery, the prepared valve with its delivery system is inserted through the apex and deployed under fluoroscopic guidance. Valve function and position is again assessed by TEE and fluoroscopy and similar to TF procedures re-ballooning might be indicated in case of significant paravalvular leaks. After the removal of all sheaths and guide wires, the apex is closed with the prepared purse-strings. A detailed step-by-step description for TA-AVI has been published earlier.⁽²⁶⁾

Advantages of the TA approach are the short distance between the apex and the aortic valve, which might allow for a more precise implantation and there is no limitation in sheath diameter. The avoidance of the retrograde crossing of the aortic arch is another great advantage of TA-AVI and it might be reflected by the trend towards lower stroke rates with TA.⁽²⁷⁻²⁹⁾

PATIENT OUTCOME AFTER TAVI

Since the beginning of TAVI experience it has evolved to a standardised and reproducible technique in specialised centres. The overall mortality for TAVI in larger studies varies now between 3 and 11%.^(1,24,30-33) An explanation for the range in mortality might be the patient selection. The good outcome from the PARTNER (Placement of AoRTic TraNscathetER Valve) trials may result from the fact that most of the patients were on a waiting list and the sicker patients might have died before the procedure due to their co-morbidities. In Europe TAVI has now become established as an "all-comers" treatment with even emergency TAVI procedures being performed, which might result in worse outcome when compared to highly selected series.

For post-operative aortic regurgitation > I+ the range is even wider. It varies between 4% and 18%.^(1,24,29,31,34-39) Besides the clinical outcome, the quality of life in this elderly high risk patient group is

also very important. It has already been demonstrated that TAVI leads to an improvement in quality of life, which is comparable with an elderly healthy matched population.^(40,41)

When comparing TA versus TF, some studies show a trend towards higher mortality in TA patients. A closer look to the risk profile of the patients in most of these studies reveals the reason for this difference: Many centres have a "TF first" strategy, where TA is only performed, when TF is not possible. This leads to a higher risk profile in the TA group and this again leads to worse outcome.^(1,24,29,31,42) Besides the relatively lower risk profile in the TF population there is a trend towards higher incidence of peri-operative strokes and most notably a higher incidence of post-operative complications in the conducting system leading to an incidence of post-operative pacemaker implantation in up to 39% of TF patients whenever a CoreValve prosthesis is used.^(27,29,31,39,43)

With the PARTNER trial the first randomised controlled comparison between TAVI, medical treatment and conventional AVR was performed. The results once again demonstrated the poor outcome for patients with severe symptomatic AS who receive only medical treatment as standard therapy. Their 1-year survival was 49.3% versus 69.3% for TAVI. Regarding cardiac symptoms the incidence of NYHA Class III-IV among the 1-year survivors was lower with TAVI compared to standard therapy.⁽¹⁾ In cohort A of the PARTNER trial, TAVI was compared to conventional AVR and it demonstrated a better 30-day survival for TAVI (96.5% vs. 93.5%), but a comparable survival after one year (75.8% for TAVI vs. 73.2% for AVR).⁽²⁴⁾

FUTURE PERSPECTIVES

The concept of TAVI itself and the associated TAVI devices are at a very early stage. Therefore it is not possible to draw any conclusion about long term durability or outcome. For this reason TAVI should remain restricted as an alternative treatment option for elderly high risk patients only. Based on the currently available data there is no rationale to expand the indication for TAVI to younger patient groups.

New indications for TAVI include degenerated xenografts in the aortic position, as well as in the mitral or even the tricuspid position. These so called valve-in-valve procedures have been performed by some centres and seem to lead to good results.^(19-21,44)

Several new transcatheter valves with different features are being developed. The JenaValve™ and the Symetis ACURATE™ are valve systems that have recently obtained CE-mark approval while their pivotal trials have been completed. Both valves are initially designed for the TA approach with a transfemoral version under development. Both are porcine valves on a self-expandable nitinol stent and allow for anatomical orientation of the valve prosthesis inside the native annulus. A new valve for the TF approach is the Portico™ from St Jude Medical. Its pivotal trial will start soon. There are a huge number of other new valve designs from different companies, but most of them are still at the level of animal feasibility studies.

There is also some development for the 2 available valve types: The CoreValve® system recently underwent a modification to ease precise valve deployment and a larger CoreValve® (31mm) has been introduced recently. With every new development the sheath diameter is decreasing, leading to less frequent major vessel complications. The Edwards SAPIEN™ valve is in its second generation, as the SAPIEN XT™ with some stent and leaflet modifications and an additional 29mm transapical valve. The sheath diameter for the TF approach of the SAPIEN™ was also decreased over the last years. The newest generation (Esheath™) – an expandable sheath which could result in even smaller diameters – has entered first clinical trials.

The transaortic aortic valve implantation has been introduced as an alternative approach for implanting the CoreValve® prosthesis in patients with pronounced peripheral vascular disease where a transfemoral approach is not possible. After performing either an upper partial sternotomy or a parasternal mini-thoracotomy, the ascending aorta is punctured and the valve is implanted retrogradely analogous to the transfemoral approach.⁽⁴⁵⁾

THE HEART TEAM AND THE SURGEON'S ROLE

TAVI combines imaging, interventional techniques, surgical techniques and general treatment of elderly high risk patients. This makes it a complex procedure, which should be performed by a "heart team" including cardiac surgeons, cardiologist and cardiac anaesthetists. In our opinion, establishing a successful TAVI programme requires launching such a heart team. Every member of the team equally contributes his competence to this team. The cardiologists are trained in catheterisation including the handling of the

fluoroscopic system. This is not only important for the TAVI procedure itself, but also for controlling some potential complications of the procedure, like occlusion of the coronaries.

The cardiac anaesthetists are routinely trained in performing intra-operative TEE and haemodynamic management.

The cardiac surgeons are probably most experienced in treating aortic valve stenosis. Over the last decades the cardiac surgeons gained a wide knowledge of the pathology and anatomy of the aortic valve by conventional open heart AVR. This knowledge is not only important during the TAVI procedure itself, but also for pre-operative patient selection. The surgical experience also plays a role in pre-operative patient's risk assessment. If a patient has some co-morbidities that are not represented by the typical risk scoring systems, it is important to identify these as potential risk factors and to evaluate if this specific patient is at high risk for conventional AVR. For the TA approach it is of course mandatory to have some surgical skills for the mini-thoracotomy, the apical exposure and closure. Especially if any complication, such as apical bleeding, occurs during TA access a cardiac surgeon would be able to solve it. The experience of a cardiac surgeon is important in case of major complications for both the TA and TF approach. The need for cardio-pulmonary bypass should always be an option, as well as conversion to conventional open-heart surgery (AVR, bypass grafting, replacement of the ascending aorta or annular rupture). Another possible complication is a tear or rupture of the femoral vessels, which might require a surgical cut-down and repair.

In summary, a TAVI procedure should not be performed without a cardiac surgeon. TF-AVI is not a purely "cardiologist's cath lab procedure" and neither should TA-AVI be performed by cardiac surgeons only.

TAVI is not the only new catheter-based treatment option for cardiac diseases former exclusively treated by cardiac surgeons. New devices for the mitral valve (MitraClip e.g.) are also available. Due to these changes in treatment options, it might become important for cardiac surgeons to gain some "wire skills" in future. Some centres have already started a rotation for cardiac surgery residents into the cath lab to learn the basics of cardiac catheterisation and even some routine PCI. This may be a good way to establish a modern type of cardiac surgeon with the option to operate as a catheter-based interventionalist.

CONCLUSION

Transcatheter aortic valve implantation has evolved into a routine procedure for elderly high risk patients with severe aortic stenosis in specialised centres. It is associated with good outcome. It is truly minimally invasive and avoids the use of cardio-pulmonary bypass and cardioplegic arrest. Both approaches - the transfemoral and the transapical - have their specific advantages, but also some approach-related disadvantages. In our opinion there are some major advantages for the TA-AVI (for example, better control of positioning and implantation and no retrograde crossing of the aortic arch), which justifies an even and fair split of cases (TF vs TA) within a true "heart team". No hard data which proves the superiority of one approach over the other, is available yet. Over the last years the outcome after TAVI has generally improved, as more and more centres gain experience in these methods.

TAVI must be a team approach where cardiologists and cardiac surgeons play an equal role and should not be performed without a cardiac surgeon.

Conflict of interest: none declared.

REFERENCES

- Leon MB, Smith CR, Mack M, et al. Transcatheter aortic valve implantation for aortic stenosis in patients who cannot undergo surgery. *N Engl J Med* 2010; 363:1597-607.
- Varadarajan P, Kapoor N, Bansal RC, et al. Clinical profile and natural history of 453 nonsurgically managed patients with severe aortic stenosis. *Ann Thorac Surg* 2006;82:2111-5.
- Brown ML, Pellikka PA, Schaff HV, et al. The benefits of early valve replacement in asymptomatic patients with severe aortic stenosis. *J Thorac Cardiovasc Surg* 2008;135:308-15.
- Grossi EA, Schwartz CF, Yu PJ, et al. High risk aortic valve replacement: Are the outcomes as bad as predicted? *Ann Thorac Surg* 2008;85:102-6; discussion 107.
- Murtuza B, Pepper JR, Stanbridge RD, et al. Minimal access aortic valve replacement: Is it worth it? *Ann Thorac Surg* 2008;85:1121-31.
- Filsoufi F, Rahmanian PB, Castillo JG, et al. Excellent early and late outcomes of aortic valve replacement in people aged 80 and older. *J Am Geriatr Soc* 2008;56:255-61.
- Melby SJ, Zierer A, Kaiser SP, et al. Aortic valve replacement in octogenarians: Risk factors for early and late mortality. *Ann Thorac Surg* 2007;83:1651-6; discussion 1656-7.
- Nicolini F, Beghi C, Barbieri F, et al. Aortic valve replacement in octogenarians: Analysis of risk factors for early and late mortality. *J Heart Valve Dis* 2010;19: 615-22.
- Bouma BJ, van Den Brink RB, van Der Meulen JH, et al. To operate or not on elderly patients with aortic stenosis: The decision and its consequences. *Heart* 1999;82:143-8.
- Iung B, Cachier A, Baron G, et al. Decision-making in elderly patients with severe aortic stenosis: Why are so many denied surgery? *Eur Heart J* 2005;26:2714-20.
- Cribier A, Eltchaninoff H, Bash A, et al. Percutaneous transcatheter implantation of an aortic valve prosthesis for calcific aortic stenosis: First human case description. *Circulation* 2002;106:3006-8.
- Webb JG, Chandavimol M, Thompson CR, et al. Percutaneous aortic valve implantation retrograde from the femoral artery. *Circulation* 2006;113:842-50.
- Grube E, Laborde JC, Gerckens U, et al. Percutaneous implantation of the CoreValve self-expanding valve prosthesis in high-risk patients with aortic valve disease: The Siegburg first-in-man study. *Circulation* 2006;114:1616-24.
- Dewey TM, Walther T, Doss M, et al. Transapical aortic valve implantation: An animal feasibility study. *Ann Thorac Surg* 2006;82:110-6.
- Lichtenstein SV, Cheung A, Ye J, et al. Transapical transcatheter aortic valve implantation in humans: Initial clinical experience. *Circulation* 2006;114:591-6.
- Walther T, Falk V, Borger MA, et al. Minimally invasive transapical beating heart aortic valve implantation—proof of concept. *Eur J Cardiothorac Surg* 2007;31: 9-15.
- Vahanian A, Alfieri O, Al-Attar N, et al. Transcatheter valve implantation for patients with aortic stenosis: A position statement from the European Association of Cardio-Thoracic Surgery (EACTS) and the European Society of Cardiology (ESC), in collaboration with the European Association of Percutaneous Cardiovascular Interventions (EAPCI). *Eur Heart J* 2008;29:1463-70.
- Kempfert J, Van Linden A, Linke A, et al. Transapical aortic valve implantation: therapy of choice for patients with aortic stenosis and porcelain aorta? *Ann Thorac Surg* 2010;90:1457-61.
- Kempfert J, Van Linden A, Linke A, et al. Transapical off-pump valve-in-valve implantation in patients with degenerated aortic xenografts. *Ann Thorac Surg* 2010;89:1934-41.
- Pasic M, Unbehaun A, Dreyse S, et al. Transapical aortic valve implantation after previous aortic valve replacement: Clinical proof of the "valve-in-valve" concept. *J Thorac Cardiovasc Surg* 2010.
- Webb JG, Wood DA, Ye J, et al. Transcatheter valve-in-valve implantation for failed bioprosthetic heart valves. *Circulation* 2010;121:1848-57.
- Ferrari E, Locca D, Sulzer C, et al. Successful transapical aortic valve implantation in a congenital bicuspid aortic valve. *Ann Thorac Surg* 2010;90:630-2.
- Wijesinghe N, Ye J, Rodes-Cabau J, et al. Transcatheter aortic valve implantation in patients with bicuspid aortic valve stenosis. *JACC Cardiovasc Interv* 2010; 3:1122-5.
- Smith CR, Leon MB, Mack MJ, et al. Transcatheter versus surgical aortic valve replacement in high risk patients. *N Engl J Med* 2011;364:2187-98.
- Kempfert J, Walther T, Borger MA, et al. Minimally invasive off-pump aortic valve implantation: The surgical safety net. *Ann Thorac Surg* 2008;86:1665-8.
- Walther T, Dewey T, Borger MA, et al. Transapical aortic valve implantation: Step-by-step. *Ann Thorac Surg* 2009;87:276-83.
- Eltchaninoff H, Prat A, Gilard M, et al. Transcatheter aortic valve implantation: Early results of the FRANCE (FRench Aortic National CoreValve and Edwards) registry. *Eur Heart J* 2011;32:191-7.
- Lefevre T, Kappetein AP, Wolner E, et al. One year follow-up of the multicentre European PARTNER transcatheter heart valve study. *Eur Heart J* 2011;32:148-57.
- Bleiziffer S, Ruge H, Mazzitelli D, et al. Survival after transapical and transfemoral aortic valve implantation: Talking about two different patient populations. *J Thorac Cardiovasc Surg* 2009;138:1073-80.
- Pasic M, Buz S, Dreyse S, et al. Transapical aortic valve implantation in 194 patients: Problems, complications and solutions. *Ann Thorac Surg* 2010;90: 1463-9; discussion 1469-70.
- Wendler O, Walther T, Schroefel H, et al. The SOURCE Registry: What is the learning curve in transapical aortic valve implantation? *Eur J Cardiothorac Surg* 2010.
- Walther T, Schuler G, Borger MA, et al. Transapical aortic valve implantation in 100 consecutive patients: Comparison to propensity-matched conventional aortic valve replacement. *Eur Heart J* 2010;31:1398-403.
- Rodes-Cabau J, Webb JG, Cheung A, et al. Transcatheter aortic valve implantation for the treatment of severe symptomatic aortic stenosis in patients at very high or prohibitive surgical risk: Acute and late outcomes of the multicentre Canadian experience. *J Am Coll Cardiol* 2010;55:1080-90.
- Dworakowski R, MacCarthy PA, Monaghan M, et al. Transcatheter aortic valve implantation for severe aortic stenosis: A new paradigm for multidisciplinary intervention: A prospective cohort study. *Am Heart J* 2010;160:237-43.
- Piazza N, Grube E, Gerckens U, et al. Procedural and 30-day outcomes following transcatheter aortic valve implantation using the third generation (18 Fr) corevalve revalving system: Results from the multicentre, expanded evaluation registry 1-year following CE mark approval. *EuroIntervention* 2008;4:242-9.
- Thomas M, Schymik G, Walther T, et al. Thirty-day results of the SAPIEN aortic Bioprosthesis European Outcome (SOURCE) Registry: A European registry of transcatheter aortic valve implantation using the Edwards SAPIEN valve. *Circulation* 2010;122:62-9.
- Van Linden A, Kempfert J, Rastan AJ, et al. Risk of acute kidney injury after minimally invasive transapical aortic valve implantation in 270 patients. *Eur J Cardiothorac Surg* 2010.
- Walther T, Kasimir MT, Doss M, et al. One-year interim follow-up results of the TRAVERSE trial: The initial feasibility study for transapical aortic valve implantation. *Eur J Cardiothorac Surg* 2011;39:532-7.
- Zahn R, Gerckens U, Grube E, et al. Transcatheter aortic valve implantation: First results from a multicentre real-world registry. *Eur Heart J* 2011;32:198-204.
- Gotzmann M, Hehen T, Gerding A, et al. Short term effects of transcatheter aortic valve implantation on neurohormonal activation, quality of life and 6-minute walk test in severe and symptomatic aortic stenosis. *Heart* 2010;96:1102-6.
- Krane M, Deutsch MA, Bleiziffer S, et al. Quality of life among patients undergoing transcatheter aortic valve implantation. *Am Heart J* 2010;160:451-7.
- Ferrari E, von Segesser LK. Transcatheter aortic valve implantation (TAVI): State of the art techniques and future perspectives. *Swiss Med Wkly* 2010;140:w13127.
- Khawaja MZ, Rajani R, Cook A, et al. Permanent Pacemaker Insertion After CoreValve Transcatheter Aortic Valve Implantation: Incidence and Contributing Factors (the UK CoreValve Collaborative). *Circulation* 2011;123:951-60.
- Walther T, Kempfert J, Borger MA, et al. Human minimally invasive off-pump valve-in-valve implantation. *Ann Thorac Surg* 2008;85:1072-3.
- Latsios G, Gerckens U, Grube E. Transaortic transcatheter aortic valve implantation: A novel approach for the truly "no-access option" patients. *Catheter Cardiovasc Interv* 2010;75:1129-36.