

Image in cardiology

Rik De Decker*, George Comitis#, Will Border† and Jo Degiovanni‡

*School of Child and Adolescent Health, University of Cape Town, South Africa

#Red Cross War Memorial Children's Hospital, Cape Town, South Africa

†Children's Healthcare of Atlanta, Emory University School of Medicine, Atlanta, Georgia, United States of America

‡Birmingham Children's Hospital NHS Trust, Birmingham, United Kingdom

Address for correspondence:

Rik De Decker
Red Cross War Memorial Children's Hospital
Klipfontein Road
Mowbray
7700
South Africa

Email:

rik.dedecker@uct.ac.za

Large coronary arterial fistulae (CAF) in children are rare, but occasionally haemodynamically significant lesions are found that require occlusion. Usually encountered incidentally (or in combination with other congenital cardiac lesions), the exact incidence and frequency of symptomatic fistulae are unknown.⁽¹⁾ Recently, transcatheter occlusion has become favoured over surgical ligation⁽²⁾ since it is safe, effective and carries few serious complications.⁽³⁾ Examples of complications include distal embolisation of the device and inadvertent obstruction of coronary arteries arising from the fistula. Placing the occluding device into the narrowest section of the fistula and using a device approximately twice the size of that diameter may prevent distal embolisation. A more unusual complication is the obstruction of coronary arteries (either arising from the fistula, or arising normally just proximal to the fistula) as a consequence of a proximally propagating thrombus in the fistula after its distal transcatheter occlusion (Prof Antoinette Cilliers, pers. comm.).

Using an Amplatzer®AVP2 (St Jude Medical, USA),⁽⁴⁾ we occluded a large CAF in a 2 year 4 month old girl who was in mild congestive cardiac failure. The case was performed during, and transmitted live, from the Red Cross War Memorial Children's Hospital to the

6th World Congress of Paediatric Cardiology and Cardiac Surgery in Cape Town, South Africa in February 2013.

The fistula arose from the left coronary sinus, coursed posterolaterally around the left atrium and then medially to empty into the right ventricle immediately below the posterior leaflet of the tricuspid valve. Its largest diameter was 12mm, and its smallest diameter 5.6mm, within a narrower segment near the exit point into the RV (Figure 1).

The aims of safe and effective occlusion of a CAF are fourfold:

- Reduction or cessation of flow through the fistula.
- Placing the device in a stable position to avoid distal migration and embolisation.
- Avoiding occlusion of coronary arteries arising from the fistula.
- Avoiding thrombosis of the fistula if it gives rise to coronary arteries.

Catheterisation (Figure 2) revealed left and right coronary arteries arising normally from the aorta with normal course and anatomy. Initial ascending aorta angiography failed to show any coronary arteries arising directly from the fistula. A 0.018" coronary guide wire passed readily through the fistula and was placed into the left pulmonary artery. Over this wire, a Berman angiographic balloon catheter was passed and inflated at the narrowest point of the fistula, temporarily occluding it. No ECG changes suggesting myocardial ischaemia were noted after 10 minutes of occlusion. However, angiography within the balloon occluded fistula, clearly revealed 3 small but significant coronary arteries supplying the inferior left ventricular myocardium. These coronary arteries arose immediately proximal to the narrowest section of the fistula. It was therefore imperative that the plug was placed within this stenosed segment, distal to the coronary arteries.

In addition, it was suggested that some flow should be allowed through the plug in order to: (a) perfuse the coronary arteries and (b) minimise the risk of thrombosis. Clearly, accurately judging the amount of residual flow is not possible, but marginally under sizing the device should result in a significant reduction of shunting, without compromising safety. The risk of a return to high flow is low and the residual shunt can be assessed by TOE immediately after placement and on subsequent transthoracic echocardiography.

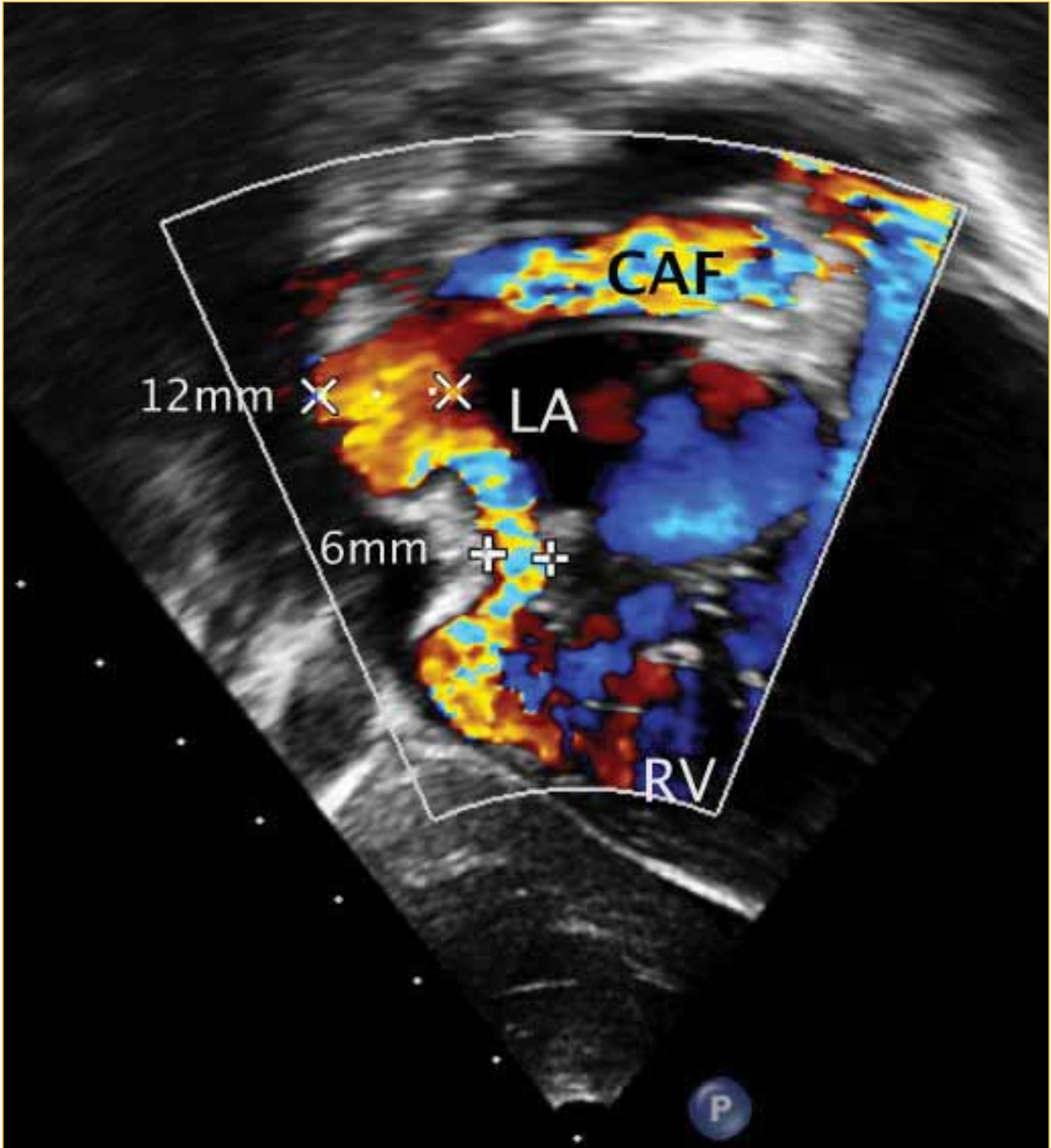


FIGURE 1: Posteriorly tilted off-axis subcostal view of a large coronary artery fistula (CAF) from the left coronary sinus to the right ventricle. The narrowest diameter is approximately 6mm.

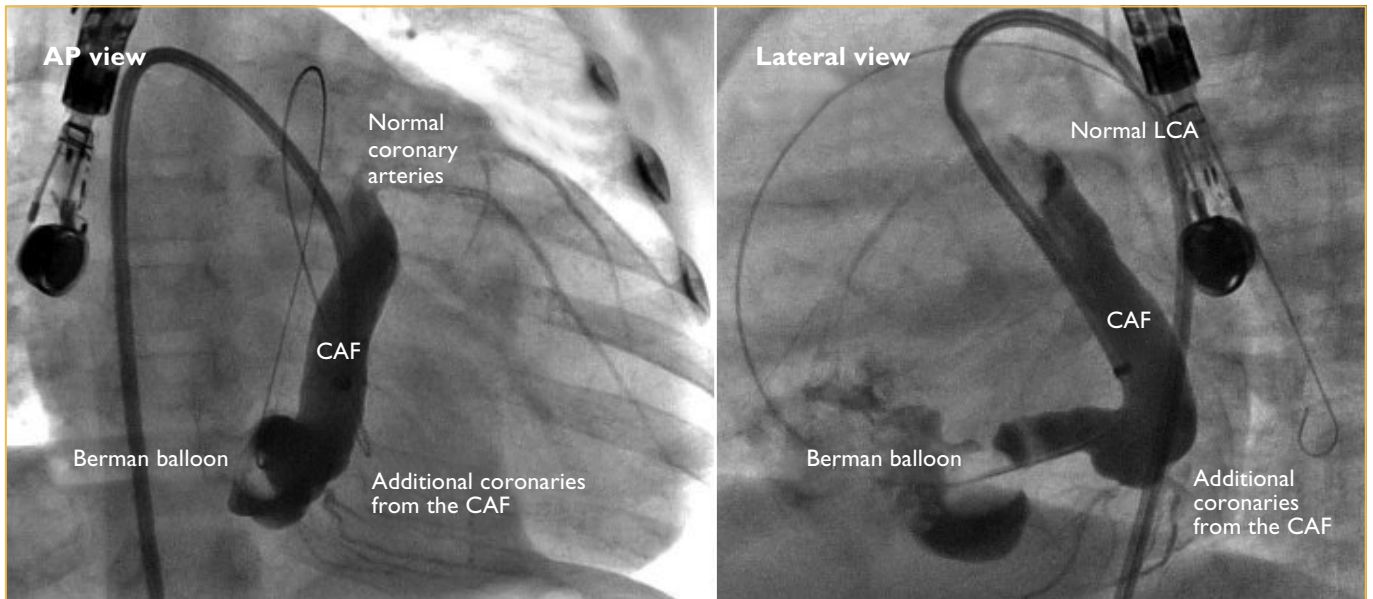


FIGURE 2: Anteroposterior and lateral views of Berman balloon occlusion of the distal coronary arterial fistula, showing normal left coronary artery anatomy immediately adjacent the origin of the fistula from the aorta. In addition, 3 additional small coronary arteries can be seen to arise from the fistula proximal to the Berman balloon and they supply the inferior left ventricular myocardium.

After discussion, it was decided that a 10mm AVP 2 plug would be deployed into the 5.6mm stenosed segment. This was chosen in preference to a 12mm AVP for the reasons given. The plug was deployed without difficulty into the narrow segment without occluding the small coronary arteries and without protruding into the RV. There was no compression of the coronary sinus or impingement on the tricuspid valve, as evidenced by TOE. Only a small amount of residual flow was noted.

On transthoracic echocardiography the following day and one week later, the same small residual flow was noted using colour Doppler at low Nyquist settings (Figure 3).

In conclusion, in certain patients, occlusion of a CAF with cessation of all flow through the fistula may not be the ideal result. Transcatheter occlusion techniques have advanced to a degree that subtle choices of device size and position are possible and may be required to best suit the anatomical demands of a specific situation. This case illustrates that the correct, undersized, plug choice allows residual, but haemodynamically insignificant flow through the fistula to minimise the risk of thrombosis with resultant obstruction of coronary artery flow.

"...le mieux est l'ennemi du bien" Voltaire (1764), Dictionnaire Philosophique.

Conflict of interest: none declared.

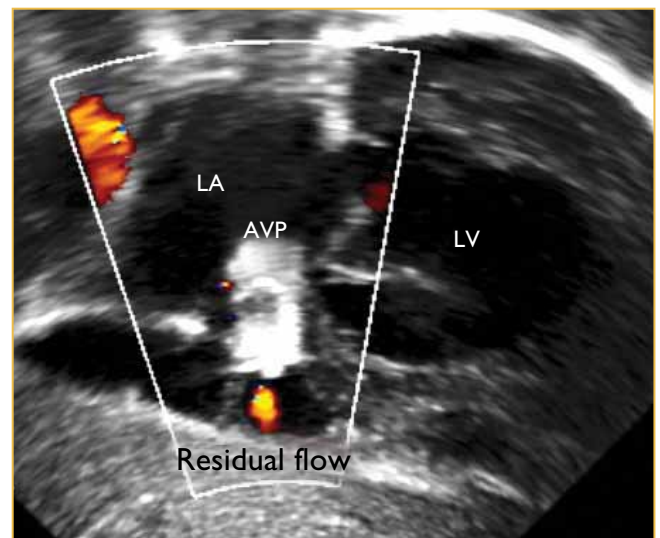


FIGURE 3: Transthoracic echocardiography of the CAF with the Amplatzer® AVP2 in situ. The red colour Doppler signal below the plug (AVP) indicates a small amount of residual flow through the plug.

REFERENCES

1. Qureshi S. Coronary arterial fistulas. *Orphanet journal of rare diseases* 2006;1:51.
2. Okamura T, et al. Effective long-term surgical management of congenital coronary artery fistulas. *Tohoku J Exp Med* 2011;223:205-209.
3. Wiegand G, et al. Transarterial and transvenous approach for transcatheter closure of a large coronary artery fistula with the Amplatzer vascular plug. *Paediatr Cardiol* 2009;30:172-175.
4. Baspinar O, et al. Retrograde transcatheter closure of large coronary fistulas with the Amplatzer vascular plug in children. *Cardiology in the young* 2011;21:104-106.