

Non-invasive imaging in congenital heart disease

Rafael Alonso-Gonzalez and Lorna Swan

Adult Congenital Heart Disease Unit, Royal Brompton Hospital,
London, United Kingdom

Address for correspondence:

Dr Lorna Swan
Royal Brompton Hospital
Sydney Street
London
SW3 6NP
United Kingdom

Email: l.swan@rbht.nhs.uk

INTRODUCTION

Congenital heart disease (CHD) comprises a heterogeneous group of structural cardiac defects present in an estimated 8 cases per 1 000 live births.⁽¹⁾ While some defects are trivial and others may close spontaneously during childhood, about 6 infants per 1 000 births will have a severe or moderate-severe form of congenital heart disease.⁽¹⁾

The outcome of these patients has changed significantly over the few decades thanks to the major improvements in cardiovascular diagnosis, cardiac surgery and peri-operative care. Where specialist care is available over 90% of infants born with CHD now reach adulthood.⁽²⁾ The complexity of the anatomy and physiology of patients surviving with CHD is increasing, leading to the expansion of the cardiology subspecialty of adult congenital heart disease.^(3,4)

Even after successful repair, many patients are left with residual lesions, which often require one or more subsequent interventions later in life. Life-long follow-up is therefore mandatory for the complex patient to monitor the haemodynamic consequences of the defect and its complications. Advances in imaging have played a role in the outcome of patients with CHD. A more comprehensive initial diagnosis has led to highly tailored surgical strategy and therefore an improved outcome. Furthermore, perioperative imaging with multi-plane, 3D transoesophageal echocardiogram had improved the real-time acquisition of both anatomical and functional data – further improving surgical results. Imaging is also

ABSTRACT

The care of the adult patient with congenital heart disease is becoming increasingly complex. In many of these patients re-intervention, heart failure and arrhythmias are inevitable consequences of successful repair in childhood. Specialist imaging is integral to accurate diagnosis and in establishing optimal management plans for these long-term complications. Fortunately there are now a whole series of imaging techniques available to the clinician – each with its own inherent strengths and limitations. These modalities are complementary and offer fresh insight into the unique anatomy and physiology of these conditions. This paper reviews the most commonly employed imaging techniques and their contribution to assessing a patient with a congenital heart lesion. SAHeart 2013;10:592-598

key in the follow-up of these patients to elucidate the pathophysiological mechanisms underlying cardiovascular dysfunction, to guide clinical decision-making,^(5,6) and identify patients who are likely to be at risk of adverse events.⁽⁷⁻¹⁰⁾

There are a number of imaging techniques available to the clinicians. In this review we will discuss the more widely used non-invasive imaging tools and their role in the diagnosis and follow-up of patients with congenital lesions.

IMPORTANCE OF SPECIALIST CENTRES

Many patients with CHD will reach adulthood after having undergone at least one, if not several, corrective or palliative surgeries during early life. It is important for imaging specialists to understand the palliative shunts, surgical repairs and reconstructive procedures used, some of which have changed significantly over the years. It is also important to know the relevant residual lesions and likely complications for each condition in order to decide the most appropriate imaging technique. Each technique has its strengths and its limitations. Echocardiography with all its modalities is an excellent tool to assess anatomy and physiology; computed tomography (CT) has a place in evaluating vascular anatomy and in particular the coronary artery anatomy when it is electrocardiogram (ECG)-synchronised; and cardiac magnetic resonance (CMR) has the ability to assess anatomy, function, and physiology without

exposure to ionising radiation. However, without the relevant expertise to acquire and interpret imaging in congenital patients, the information obtained may be inaccurate or may mislead the clinical decision-making. It is, therefore, recommended that imaging is undertaken by a specialist team with experience following up these patients.⁽¹¹⁾

WHAT IS IMPORTANT IN CONGENITAL HEART DISEASE IMAGING?

When assessing patients with suspected CHD for the first time, one should assume that every vein, artery, chamber and connection is abnormal until proven otherwise. Segmental sequential analysis is necessary to assess the heart's anatomy and connections. This begins by determining the atrial arrangement (situs), which can be "usual" (situs solitus), "inverted" (situs inversus) or can be a bilateral duplication of the one type of atrium, known as right or left atrial "isomerism". Atrio-ventricular and ventriculo-arterial connections are described as "concordant" (e.g. left atrium connecting to the left ventricle (LA-LV) or right ventricle connecting to the pulmonary artery (RV-PA), as discordant (e.g. right atrium to LV) or as a

common atrio-ventricular connection. It is also possible for both inflow or outflow valves to connect predominantly to one ventricle ("double inlet" when both atrio-ventricular valve open to the same ventricle, or "double outlet" when both great vessels arise from the same chamber). Finally, it is also possible that one of the atrio-ventricular or ventriculo-arterial connections is absent (e.g. tricuspid atresia or pulmonary atresia). Transposition of the great arteries (TGA) is an example of discordant ventriculo-arterial connections, which results in an altered relationship between the great vessels. Instead of the normal crossover of spiral relationship, in TGA hearts the two vessels run parallel to each other, an echocardiographic feature that helps to make the diagnosis in a cyanosed neonate.

In addition, the presence of one congenital heart defect increases the possibility of there being other defects – there therefore needs to be a meticulous system for studying each component of the heart. For example, pulmonary atresia may exist with or without a ventricular septal defect or with or without confluent pulmonary arteries. No matter what imaging technique is being utilised this methodical and ordered manner of studying the heart will ensure an accurate and comprehensive report irrespective of the complexity of the underlying condition.

TABLE 1: An example of how complementary imaging techniques are used to assess a patient with repaired Tetralogy of Fallot

Technique	Key Strengths (ability to describe & assess)
CXR	Presence of previous thoracotomies & sternotomy
	Presence of a right sided aortic arch
	Size of the pulmonary arteries
	Degree of cardiomegaly
	Relative size of the lungs & pulmonary blood flows
	Calcification in conduits
Echo	Biventricular size and function
	Presence & significance of any residual VSD
	Aortic root dilatation
	Valve regurgitation esp. pulmonary & tricuspid valves
	Restrictive physiology of RV & RA size
CMR	Biventricular function & volumes
	Accurate quantification of pulmonary regurgitant fraction
	Anatomy of the RV outflow tract & PA
	Aortic root & ascending aortic dilatation
	Old BT shunts (?closed)
	Aortopulmonary collateral
	Late gadolinium scarring of the RV & LV
CT scan	Coronary arteries
	Old BT shunts and collaterals
	Assess calcification of the RVOT & suitability for percutaneous intervention on the pulmonary valve

CXR = chest X-ray. Echo = echocardiography. CMR = cardiac magnetic resonance. CT scan = computed tomography scan.

DIFFERENT IMAGING MODALITIES

The most common imaging modalities used to diagnose and follow-up patients with congenital heart disease are echocardiography, CMR and CT-scan. However, simpler techniques, such as chest radiography (Table 1) or even more complex such as angiography, might be also needed, depending on the type of congenital heart disease.

Chest radiography

Postero-anterior chest radiography provides valuable and inexpensive information in patients with congenital lesions. In almost all patients atrial arrangement corresponds to that of the bronchi, but not always to that of the abdominal organs. Thus, the visibility of a long pre-branch segment with passage inferior to the corresponding pulmonary artery of a left main bronchus, or of a shorter pre-branch segment with passage superior to the corresponding pulmonary artery of a right main bronchus, gives useful information of the atrial morphology (Figure 1).

Cardiomegaly, an independent marker of disease severity and outcome in patients with congenital heart disease,⁽¹²⁾ is easily assessed in a postero-anterior chest X-ray (CXR). Signs of previous surgery including sternal wires from sternotomy and rib asymmetry from childhood thoracotomy can also be useful diagnostic features.

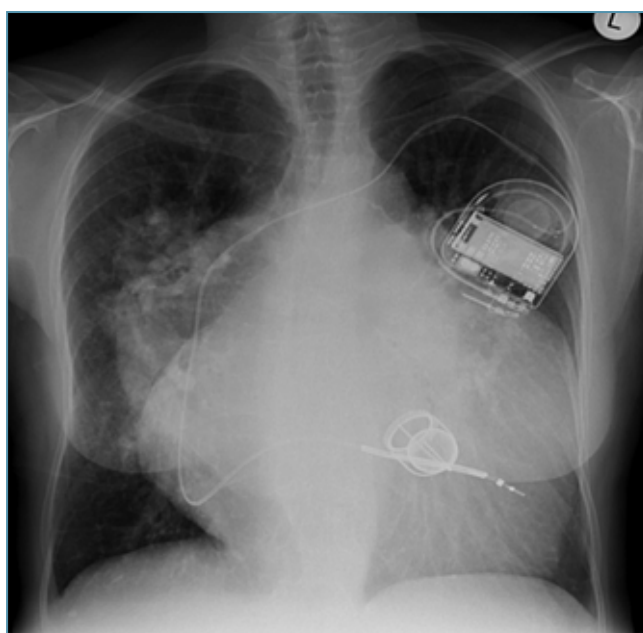
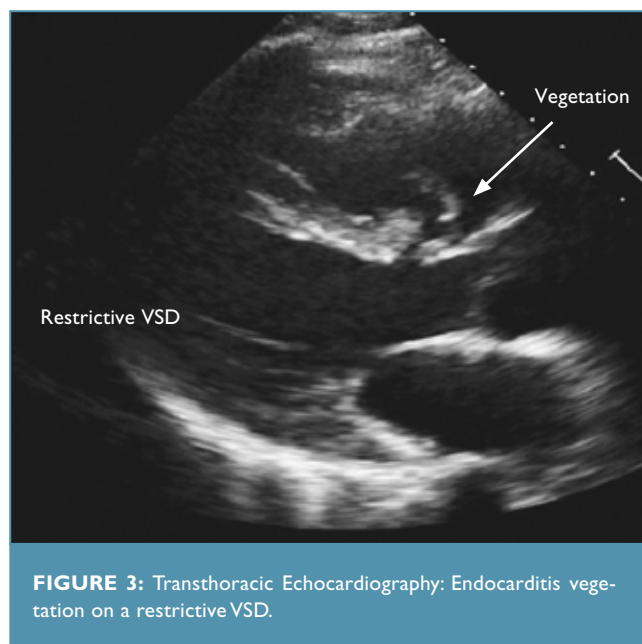
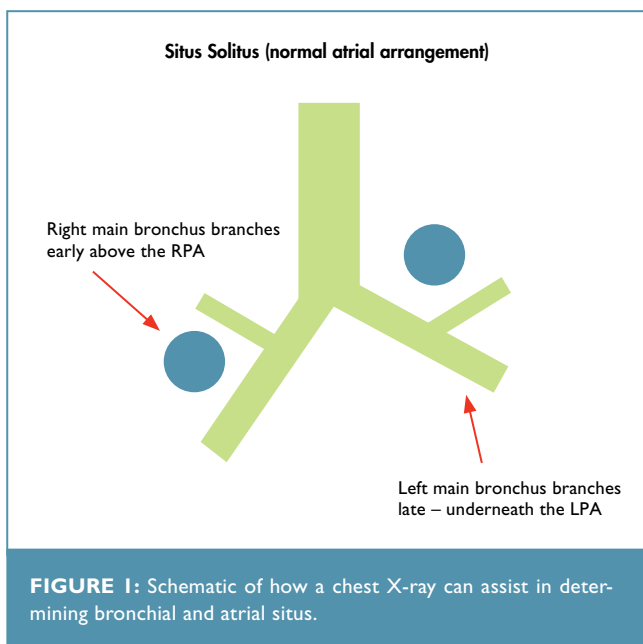


FIGURE 2: Plain chest X-ray in a patient with congenitally corrected transposition (CCTGA) and a VSD with severe pulmonary hypertension. There is also a Starr Edwards systemic AV valve and single chambered defibrillator.

The chest X-ray is an excellent modality for assessing overall cardiac size and the relative size of the other cardiac chambers. X-ray is also ideal for imaging pacing wires and pacing systems.

artery or pruning of the distal pulmonary vessels may be present in patients with pulmonary arterial hypertension (Figure 2) Finally the position of the aortic arch is readily seen from a plain CXR and may indicate the presence of one of its associated lesions such as Tetralogy of Fallot.

Echocardiography

Echocardiography is the bedrock of CHD imaging both for diagnosis and for long-term follow up. Two-dimensional echocardiography is ideally suited for the evaluation of congenital heart disease because of its ability to visualise cross-sections of complex cardiac structures. In particular it is highly effective in visualising heart walls, chamber configuration, valve anatomy, intra-cardiac shunts and in revealing complex spatial morphologic information. In addition, it is the technique of choice to assess small, thin and mobile intracardiac structures such as valve leaflets, the atrial septum and endocarditis vegetations where the resolution is superior to techniques such as cardiac magnetic resonance (Figure 3). Transthoracic echocardiogram is such a useful day to day tool because its strength lies in its capability to assess, and integrate, both anatomy and physiology.

Assessment of left ventricular systolic function is reliable and reproducible, however assessing the right ventricle can be more challenging. This is in part due to the retrosternal location of the RV, its irregular geometry and trabeculated structure. The RV assessment is even more difficult in conditions of volume overload (such as Tetralogy of Fallot with pulmonary regurgitation) or

Scoliosis, which might be part of the underlying condition and/or a consequence of previous surgery, is prevalent in ACHD patients⁽¹³⁾ and is an independent predictor of lung dysfunction in this population.⁽¹³⁾ Other signs, such as dilatation of the main pulmonary

pressure overload (in TGA following an atrial switch or Mustard procedure). Accurate measure of RV size and function drives many clinical decisions in adult congenital heart disease patients and CMR is often used to more accurately measure RV volumes and function.

Echocardiography is also highly effective at assessing the level (subvalvar, valvar or supravalar) and the character of stenotic lesions (dynamic or fixed). The quantification of a gradient over a stenosed valve in combination with measurement of valve area can be used to accurately grade the haemodynamic importance of a narrowing (mild, moderate or severe).

The evaluation of valve incompetence by echocardiography is hampered by the inability to directly quantify the regurgitant volume. Furthermore, the use of echocardiography for the reliable assessment of atrio-ventricular regurgitation is also limited by the high interobserver variability of the parameters on which regurgitation severity is assessed.⁽¹⁴⁾ When assessing regurgitant lesions CMR allows a more accurate estimation of the regurgitant fraction being the technique of choice to evaluate right-sided regurgitant lesions. In this context echo and CMR are complimentary with excellent imaging resolution from echo and highly accurate haemodynamics from CMR.

Progressive aortic root dilatation is common in ACHD patients. The aortic root (and ascending aorta) may dilate in patients with a bicuspid aortic valve, especially in the presence of a coarctation,⁽¹⁵⁾ in the Ross patient, following arterial switch, in corrected or uncorrected pulmonary atresia, repaired truncus arteriosus, or long after correction of ToF.⁽¹⁶⁾ Transthoracic echocardiogram is useful to assess the aortic root and proximal ascending aorta, however it needs to be supplemented by other techniques, such as CMR or CT, to obtain reliable imaging of the ascending aorta and aortic arch (Figure 4). Residual or recurrent stenoses of vessels is commonly reported in patients with CHD, for example after coarctation of the aorta repair, or after an arterial switch operation for TGA. To estimate the peak pressure gradient across these sites continuous wave Doppler and the Bernoulli equation can be used. A diastolic velocity higher than 1.93cm/s measured at the end of the "T" wave, has a high sensitivity and specificity in predicting severe re-coarctation.⁽¹⁷⁾ However, CMR and CT are better techniques to assess extra-cardiac vessel anatomy and obstructions.

Tissue Doppler techniques have a role in the assessment of congenital heart lesions. It has been reported that the peak systolic annular velocity of the right ventricular lateral wall has a good

agreement with systolic function measure by CMR in normal and abnormal hearts.⁽¹⁸⁾ Strain and strain rate quantification have been used to study the complexities of systemic RV mechanics. It is well known that strain patterns are different in TGA patients. Moreover, it has been recently reported that global longitudinal systolic strain is significantly reduced in patients with a systemic RV.⁽¹⁹⁾ Global longitudinal strain also relates to subpulmonary ventricular function and predicts adverse clinical outcome in adults with atrial switch for TGA.⁽¹⁹⁾

In patients with CHD, real-time 3D echocardiography is an accurate and reproducible technique to visualise the cardiac and valve morphology, as well as to quantify left ventricular volumes and ejection fraction.⁽²⁰⁾ However, 3D echocardiography still underestimates right ventricular volumes.⁽²¹⁾ Real-time 3D is really useful for perioperative assessment and to guide interventions such as transaortic valve implantation or percutaneous pulmonary valve implantation.

The presence of postoperative scar, chest wall deformities, overlying lung tissue and large body size can impact on the quality of transthoracic imaging. The role of trans-oesophageal imaging will not be discussed in full but it brings with it another level of resolution. It is therefore an ideal technique for assessing anatomy

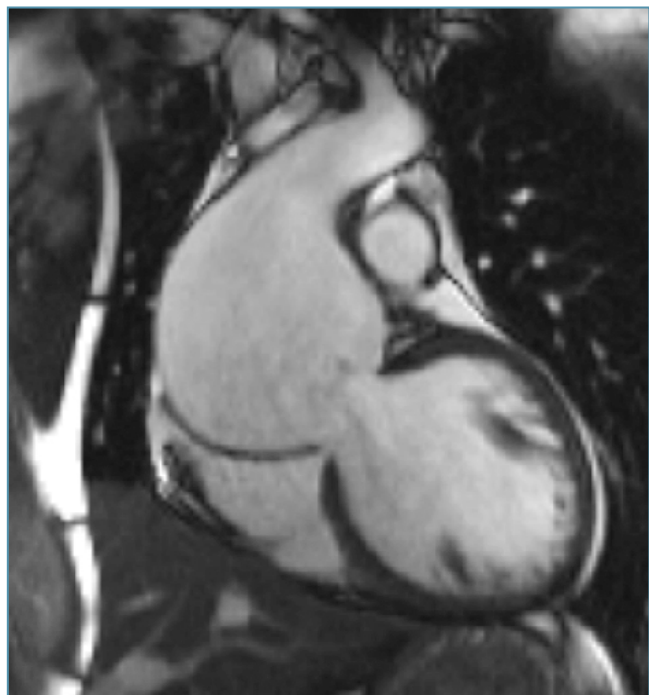

FIGURE 4: CMR imaging showing a very dilated aortic root and ascending aorta in a patient with Marfan syndrome.

in detail. Examples of this are assessing atrial septal defects prior to device closure, detecting the presence of intra-cardiac infection (endocarditis vegetations) or clot (atrial appendages) and determining the mechanisms of valve dysfunction. Intra-cardiac echo has similar properties but is more invasive.

Cardiac magnetic resonance

CMR has emerged over the past two decades as a complementary imaging modality for the investigation of anatomy and function in ACHD patients. This modality is not restricted by body size or poor acoustic windows, and it has many advantages over other imaging modalities. It does not require the use of iodinated contrast agents and does not involve exposure to ionising radiation. Moreover, the various CMR techniques, such as steady-state free-precession CMR and phase-velocity imaging allow the accurate assessment of cardiac anatomy, cardiac dimensions, and the velocity and volume of blood-flow without geometrical assumptions. The administration of contrast agents allows 3D evaluation of contrast structures, scar tissue, and fibrosis within the myocardium. In addition, major advances in MRI hardware and software, including advanced coil design, faster gradients, new pulse sequences, and faster image reconstruction techniques, allow rapid, high-resolution imaging of complex anatomy and accurate, qualitative assessment of physiology and function.⁽²²⁾ The main limitation of this technique is the long examination times required, the artifacts caused by stents and the contraindication of this technique in patients with pacemakers.

The clinical indication for CMR varies across the ACHD population. CMR might be requested to monitor the effects of residual haemodynamic lesions (e.g. pulmonary regurgitation after Tetralogy repair), guide future interventions (e.g. in patients with recoarctation of the aorta), to evaluate a vascular obstruction (e.g. baffle obstruction after an atrial switch for TGA), to rule out intracardiac clots (e.g. in patients with classic atriopulmonary Fontan) or to assess ventricular function. Perfusion imaging can also be an effective screen for coronary ischaemia.

CMR is an excellent tool to delineate complex anatomy. For example, left atrial isomerism is associated with the absence of the inferior vena cava, which leads to interruption of the vein and azygos or hemiazygos continuation, which will drain into the right or left superior vena cava, respectively. CMR is the technique of choice to delineate accurately the cardiac anatomy as well as quantifying the venous return in this setting.

The unusual shape of the RV cavity and the unpredictable manner in which it dilates make accurate quantitative analysis by echo-

cardiographic or radionuclide angiographic techniques difficult. CMR permits more accurate and reproducible quantitative analysis of RV dimensions and function in experienced hands. CMR is the gold standard technique for measuring right ventricular volumes and function in patients with CHD.⁽²³⁾ It is also the gold standard in the assessment of regurgitant lesions, especially aortic or pulmonary valve regurgitation. Pulmonary regurgitation is the commonest residual lesion after ToF repair. The pathophysiology of pulmonary regurgitation differs from that of aortic regurgitation. Free pulmonary regurgitation, with little or no effective valve function, may be tolerated without symptoms for decades and is typically associated with a regurgitant fraction of 35-45%.⁽²⁴⁾ The optimal "cut-off" value beyond which pulmonary valve replacement (PVR) should be recommended remains controversial. Lee, et al.,⁽⁵⁾ reported recently in a cohort of 170 ToF patients that, in order to obtain normalised RV volumes and function after PVR. It was suggested that surgery should be considered before the right ventricular end-diastolic volume exceeds 163ml/m² or the right ventricular end-systolic volume exceed 80ml/m². Furthermore, higher pre-operative right ventricular end-systolic volume was identified as the only independent risk factor for suboptimal outcome.

Direct quantification of regurgitant volume through an incompetent atrioventricular valve by CMR might be limited by the movement of the base of the heart toward the apex during systole and therefore several correction methods, which are beyond the scope of this review, have been proposed.

Another of CMR's strengths is its ability to assess vascular stenoses. After an arterial switch operation for transposition, in which the distal pulmonary artery and its branches are brought forward in the Lecompte manoeuvre, peripheral pulmonary artery stenoses or supra-valvar pulmonary stenoses can develop.⁽²⁵⁾ CMR can accurately assess the pulmonary artery branches and also the relative pulmonary blood flow to each lung. CMR is also the technique of choice for the long-term follow-up of those who underwent coarctation of the aorta repair. It allows detailed visualisation of recoarctation or aneurysm formation, and can be useful to plan further interventions.⁽²⁶⁾ CMR can be repeated at regular intervals without the concern of radiation exposure in the patient with a coarctation repair technique that has predisposed them to repair site aneurysms. Annual scanning may be needed in these high risk patients.⁽²⁷⁾ An exception is after deployment of a stent, when a contrast-CT study will provide better assessment of the in-stent lumen and any possible aneurysm formation in the vicinity of the stent.⁽²⁸⁾

Although echocardiography is the modality of choice to visualise intracardiac shunts, CMR is the non-invasive technique of choice to calculate the Qp:Qs (ratio of pulmonary to systemic blood flow). Ascending aortic flow is equivalent to systemic cardiac output in the presence of an intracardiac shunt. However, in patients with a patent ductus arteriosus, increased ascending aorta flow is expected and is equivalent to the amount of pulmonary flow. The smaller amount of flow measured in the pulmonary trunk will be equivalent to the systemic flow.⁽²⁷⁾

COMPUTED TOMOGRAPHY

Developments in CT techniques in the past decade have led CT to become a valuable tool for assessing the cardiovascular system. CT is emerging as a further method of imaging in this population, especially when CMR is precluded by a pacemaker or defibrillator.

Non-ECG-synchronised CT is useful for assessing extracardiac abnormalities.⁽²⁹⁻³¹⁾ However, the introduction of the ECG-synchronised scan with either retrospective, or more recently, prospective triggering allows more accurate assessment of the coronary arteries,⁽³²⁾ better assessment of the intracardiac structures and even the calculation of ventricular volumes and function.⁽³³⁾ The main limitation of CT is exposure to ionising radiation and its associated risk of cancer which makes repeat examinations unattractive. However, the prospective ECG-synchronised sequential scanning is a low-dose technique that can reduce the CT dose to 1 to 3 mSv.⁽²²⁾ Furthermore, the development of spiral

and the multi-detector computed tomography enables the acquisition of data during a single breath holding and during the first pass of a contrast bolus, reducing also the dose of radiation significantly.

The main clinical indication of CT in CHD is to assess the coronary arteries and their relations to adjacent structures. The use of percutaneous pulmonary valves is growing. When the valve is deployed there is a risk of coronary artery compression if the coronaries are in close proximity. ECG-synchronised CT is the technique of choice to assess coronary arteries and their relation to the RV-PA conduit in this setting. CT also has a very high resolution and can image structures that are difficult to see on CMR scans such as the cardiac veins (Figure 5). This improved resolution is also required before planning a complex aortic intervention such as a covered stent of a coarctation aneurysm.

CARDIAC CATHETERISATION

As imaging techniques improve the role for diagnostic cardiac catheterisation has diminished. However angiography still has a role in complex patients especially when studying vessel anatomy prior to intervention. Catheterisation also remains the gold standard in assessing haemodynamics and in the diagnosis of pulmonary arterial hypertension.

CONCLUSIONS

The evaluation and monitoring of the patient with a congenital heart lesion is demanding and each condition presents its own challenges. ACHD patients should therefore be investigated and managed in specialist centres. Over the last couple of decades clinicians have been given a large array of new imaging modalities to assist them in diagnosis and ongoing management. Echocardiography remains the first-line imaging technique although it will not be able to answer all of the clinical questions. Both CMR and ECG-synchronised CT provide complementary non-invasive information and are particularly good at describing three dimensional structures and extra cardiac vessels. Finally cardiac catheterisation is used prior to intervention or to accurately measure haemodynamics such as pulmonary vascular resistance.

Conflict of interest: none declared.

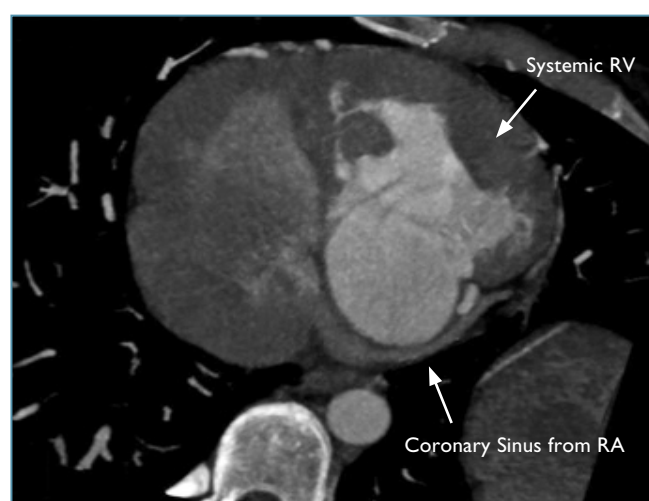


FIGURE 5: CT scan to delineate the anatomy of the coronary sinus in a patient with CCTGA – prior to planning a transvenous biventricular pacemaker.

REFERENCES

- Hoffman JL, Kaplan S. The incidence of congenital heart disease. *J Am Coll Cardiol* 2002;39:1890-1900.
- Moons P, Bovijn L, Budts W, et al. Temporal trends in survival to adulthood among patients born with congenital heart disease from 1970 to 1992 in Belgium. *Circulation* 2010;122:2264-2272.
- Perloff JK, Warnes CA. Challenges posed by adults with repaired congenital heart disease. *Circulation* 2001;103:2637-2643.
- Silversides CK, Marelli A, Beuchet L, et al. Canadian cardiovascular society 2009 consensus conference on the management of adults with congenital heart disease: Executive summary. *Can J Cardiol* 2010;26:143-150.
- Lee C, Kim YM, Lee CH, et al. Outcomes of pulmonary valve replacement in 170 patients with chronic pulmonary regurgitation after relief of right ventricular outflow tract obstruction: Implications for optimal timing of pulmonary valve replacement. *J Am Coll Cardiol* 2012;60:1005-1014.
- Oosterhof T, van Straten A, Vliegen HW, et al. Preoperative thresholds for pulmonary valve replacement in patients with corrected tetralogy of fallot using cardiovascular magnetic resonance. *Circulation* 2007;116:545-551.
- Babu-Narayan SV, Goktekin O, Moon JC, et al. Late gadolinium enhancement cardiovascular magnetic resonance of the systemic right ventricle in adults with previous atrial redirection surgery for transposition of the great arteries. *Circulation* 2005;111:2091-2098.
- Babu-Narayan SV, Kilner PJ, Li W, et al. Ventricular fibrosis suggested by cardiovascular magnetic resonance in adults with repaired tetralogy of fallot and its relationship to adverse markers of clinical outcome. *Circulation* 2006;113:405-413.
- Galleo P, Gonzalez AE, Sanchez-Recalde A, et al. Incidence and predictors of sudden cardiac arrest in adults with congenital heart defects repaired before adult life. *Am J Cardiol* 2012;110:109-117.
- Ghai A, Silversides C, Harris L, et al. Left ventricular dysfunction is a risk factor for sudden cardiac death in adults late after repair of tetralogy of fallot. *J Am Coll Cardiol* 2002;40:1675-1680.
- Kilner PJ, Geva T, Kaemmerer H, et al. Recommendations for cardiovascular magnetic resonance in adults with congenital heart disease from the respective working groups of the European Society of Cardiology. *Eur Heart J* 2010;31:794-805.
- Dimopoulos K, Giannakoulas G, Bendayan I, et al. Cardiothoracic ratio from postero-anterior chest radiographs: A simple, reproducible and independent marker of disease severity and outcome in adults with congenital heart disease. *Int J Cardiol* 2013;166:453-457.
- Alonso-Gonzalez R, Borgia F, Diller GP, et al. Abnormal lung function in adults with congenital heart disease: Prevalence, relation to cardiac anatomy, and association with survival. *Circulation* 2013;127:882-890.
- Biner S, Rafique A, Rafii F, et al. Reproducibility of proximal isovelocity surface area, vena contracta, and regurgitant jet area for assessment of mitral regurgitation severity. *JACC Cardiovasc Imaging* 2010;3:235-243.
- Oliver JM, Alonso-Gonzalez R, Gonzalez AE, et al. Risk of aortic root or ascending aorta complications in patients with bicuspid aortic valve with and without coarctation of the aorta. *Am J Cardiol* 2009;104:1001-1006.
- Niwa K, Siu SC, Webb GD, Gatzoulis MA. Progressive aortic root dilatation in adults late after repair of tetralogy of fallot. *Circulation* 2002;106:1374-1378.
- Tan JL, Babu-Narayan SV, Henein MY, et al. Doppler echocardiographic profile and indexes in the evaluation of aortic coarctation in patients before and after stenting. *J Am Coll Cardiol* 2005;46:1045-1053.
- Wang J, Prakasa K, Bomma C, et al. Comparison of novel echocardiographic parameters of right ventricular function with ejection fraction by cardiac magnetic resonance. *J Am Soc Echocardiogr* 2007;20:1058-1064.
- Diller GP, Radojevic J, Kempny A, et al. Systemic right ventricular longitudinal strain is reduced in adults with transposition of the great arteries, relates to sub-pulmonary ventricular function, and predicts adverse clinical outcome. *Am Heart J* 2012;163:859-866.
- Shirali GS. Three-dimensional echocardiography in congenital heart disease. *Echocardiography* 2012;29:242-248.
- Shimada YJ, Shiota M, Siegel RJ, Shiota T. Accuracy of right ventricular volumes and function determined by three-dimensional echocardiography in comparison with magnetic resonance imaging: A meta-analysis study. *J Am Soc Echocardiogr* 2010;23:943-953.
- Broberg C, Meadows AK. Advances in imaging: The impact on the care of the adult with congenital heart disease. *Prog Cardiovasc Dis* 2011;53:293-304.
- Luijnenburg SE, Robbers-Visser D, Moelker A, et al. Intra-observer and inter-observer variability of biventricular function, volumes and mass in patients with congenital heart disease measured by cmr imaging. *Int J Cardiovasc Imaging* 2010;26:57-64.
- Chaturvedi RR, Redington AN. Pulmonary regurgitation in congenital heart disease. *Heart* 2007;93:880-889.
- Kempny A, Wustmann K, Borgia F, et al. Outcome in adult patients after arterial switch operation for transposition of the great arteries. *Int J Cardiol* 2012.
- Grotenhuis HB, de Roos A. Structure and function of the aorta in inherited and congenital heart disease and the role of MRI. *Heart* 2011;97:66-74.
- Kilner PJ. Imaging congenital heart disease in adults. *Br J Radiol* 2011;84 Spec No 3:S258-268.
- Chessa M, Carrozza M, Butera G, et al. Results and mid-long-term follow-up of stent implantation for native and recurrent coarctation of the aorta. *Eur Heart J* 2005;26:2728-2732.
- Goo HW, Park IS, Ko JK, et al. CT of congenital heart disease: Normal anatomy and typical pathologic conditions. *Radiographics* 2003;23 Spec No:S147-165.
- Goo HW, Park IS, Ko JK, et al. Computed tomography for the diagnosis of congenital heart disease in paediatric and adult patients. *Int J Cardiovasc Imaging* 2005;21:347-365; discussion 367.
- Leschka S, Oechslin E, Husmann L, et al. Pre- and postoperative evaluation of congenital heart disease in children and adults with 64-section CT. *Radiographics* 2007;27:829-846.
- Goo HW, Seo DM, Yun TJ, et al. Coronary artery anomalies and clinically important anatomy in patients with congenital heart disease: Multislice CT findings. *Pediatr Radiol* 2009;39:265-273.
- Busch S, Johnson TR, Wintersperger BJ, et al. Quantitative assessment of left ventricular function with dual-source CT in comparison to cardiac magnetic resonance imaging: Initial findings. *Eur Radiol* 2008;18:570-575.