

These cases demonstrate dynamic LVOTO, secondary to accessory mitral valve tissue (AMVT). The presence of redundant tissue makes it easy to mistake this for a mass in the LVOT in certain echocardiographic views. This uncommon diagnosis should be included in the differential diagnosis of an LVOT mass with dynamic LVOTO. Features of AMVT include a strong association with attachment to the mitral valve (MV) or its apparatus.⁽¹⁾ The mass is often attached in the LVOT at the mitral-aortic continuity, or is pulled into the LVOT during systole due to a Venturi effect. Echocardiography demonstrated chordal attachments to the AMVL, in both our cases, and to the subvalvular apparatus in one case. Tissue echogenicity is typically that of MV tissue and myxomatous degeneration is commonly seen.^(1,2) Mild AR attributed to jet lesions were present in both our cases. AMVT has been classified to broadly indicate the level of differentiation of the tissue.⁽³⁾ Similar to management of patients with hypertrophic obstructive cardiomyopathy, where relief of LVOTO is only indicated in symptomatic patients' refractory to medical therapy,⁽⁴⁾ we elected to manage these cases expectantly with clinical and echocardiographic follow up. Patient A had an uncomplicated pregnancy and both patients remain well and asymptomatic.

Conflict of interest: none declared.

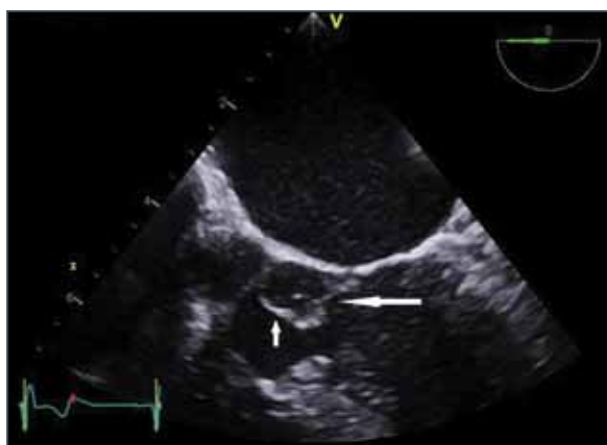


FIGURE 3: Patient A. Mid – esophageal 5 chamber TEE view illustrating chordal attachments (long arrow) from an accessory mitral valve leaflet (AMVL) (short arrow) to anterior mitral valve.

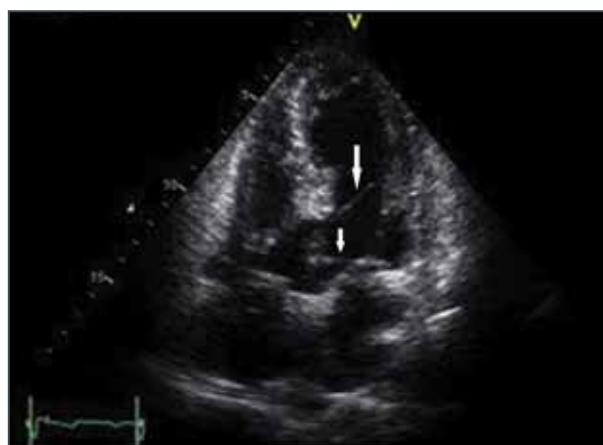

FIGURE 4: Patient B. Apical 5 chamber view illustrating chordal attachments to lateral ventricular wall (long arrow) and AMVL (short arrow) respectively.

REFERENCES

1. Manganaro R, Zito C, Khandheria BK, et al. Accessory mitral valve tissue: An updated review of the literature. *Cardiovascular Imaging* 2014;15:489-497.
2. Rao N, Gajjar T, Desai N. Accessory mitral valve tissue: an unusual cause of congenital mitral stenosis. *Interact Cardiovasc and Thorac Surg* 2012;14: 110-112.
3. Prifti E, Bonacchi M, Bartolozzi F, et al. Postoperative outcome in patients with accessory mitral valve tissue. *Med Sci Monit* 2003;9:126-133.
4. 2014 ESC Guidelines on the diagnosis and management of Hypertrophic cardiomyopathy of the European Society of Cardiology (ESC). *European Heart Journal* (2014;35:2733-2779 – doi/10. 1093/euroheartj/ehu284.