

When opportunity knocks

Annari van Rensburg, Charles Kyriakakis, Alfonso Pecoraro and Philip Herbst

Division of Cardiology, Department of Medicine, University of Stellenbosch and Tygerberg Academic Hospital, South Africa.

Address for correspondence:

Annari van Rensburg
Division of Cardiology, Department of Medicine
University of Stellenbosch and Tygerberg Hospital
PO Box 19063
Tygerberg
7505
South Africa

Email:

annarivanrensburg@gmail.com

Constrictive pericarditis remains a common medical problem in developing countries where it frequently complicates tuberculous pericarditis. In addition, it is not infrequently seen in the developed world in the context of previous cardiac surgery, chest irradiation and even idiopathic pericarditis.⁽¹⁾ The diagnosis of pericardial constriction is often elusive and delays between the onset of symptoms and final diagnosis is the norm. Given the potential curability of this cause of heart failure and the fact that various features of chronicity in the disease portend a poor prognosis, recognising the disease early is of paramount importance.⁽¹⁾ The haemodynamics of constriction, particularly in more pronounced cases, produces a set of interesting clinical findings that the vigilant physician can elicit. A useful, and often neglected clinical feature, is that of a diastolic precordial or epigastric impulse, the palpable equivalent of an audible diastolic pericardial knock. This short report illustrates this unique clinical finding and explains the haemodynamics responsible for it. We also briefly review other commonly found clinical findings that assist in making the diagnosis of constrictive pericarditis.

CLINICAL SUMMARY

A 31-year-old male patient with a longstanding history of heart failure was referred to our cardiac unit from a peripheral hospital. He had no other medical history of note and no

cardiovascular risk factors or history of substance abuse. His clinical examination revealed a raised jugular venous pulsation (JVP) that did not decrease with inspiration (Kussmaul's sign), with prominent x- and y-descents (Video 1). A prominent epigastric impulse and an additional early diastolic heart sound that varied in intensity with respiration, becoming more pronounced with inspiration, were also present (Audio 1). This additional heart sound occurred shortly after the second heart sound, during early diastole, and was most pronounced over the lower left sternal border.

The epigastric impulse was initially interpreted by the referring physician as representing a right ventricular heave. However, timing the impulse with the carotid pulsation as reference, revealed it to be a diastolic, rather than a systolic impulse. The diastolic impulse, although most prominently felt in the epigastrium, could also be detected over the precordium as far out as the cardiac apex, producing a "diastolic apex beat". The clinical diagnosis of constrictive pericarditis was subsequently confirmed on transthoracic echocardiography.

DISCUSSION

So, what causes a diastolic knock? In constriction the heart becomes encased in a rigid, and often calcified, pericardium. This results in a rigidly fixed cardiac volume – like a glass jug, the heart can fill to a certain volume and then no more. Secondly, the intracardiac and intrathoracic pressures become dissociated, leading to a different rate of filling for each ventricle, depending on the respiratory cycle (differential filling). Central to understanding the haemodynamics produced by constriction is the fact that, while the heart is encased in a rigid pericardium that effectively isolates it from the changes in intrathoracic pressure produced by respiration, the pulmonary veins lie extra-pericardially and thus remain responsive to respiratory changes. In health, negative intrathoracic pressure during inspiration is transmitted to both the pulmonary veins and the compliant pericardial space simultaneously. This drop in pericardial pressure is relayed to the left ventricular cavity, in concert with the drop in pulmonary venous pressure, and thus the gradient for left heart filling, the mitral forward driving gradient, is maintained. In constriction, the inspiratory decrease in intrathoracic pressure is transmitted to the pulmonary veins, but not to the left ventricle. The transmitral gradient is there-

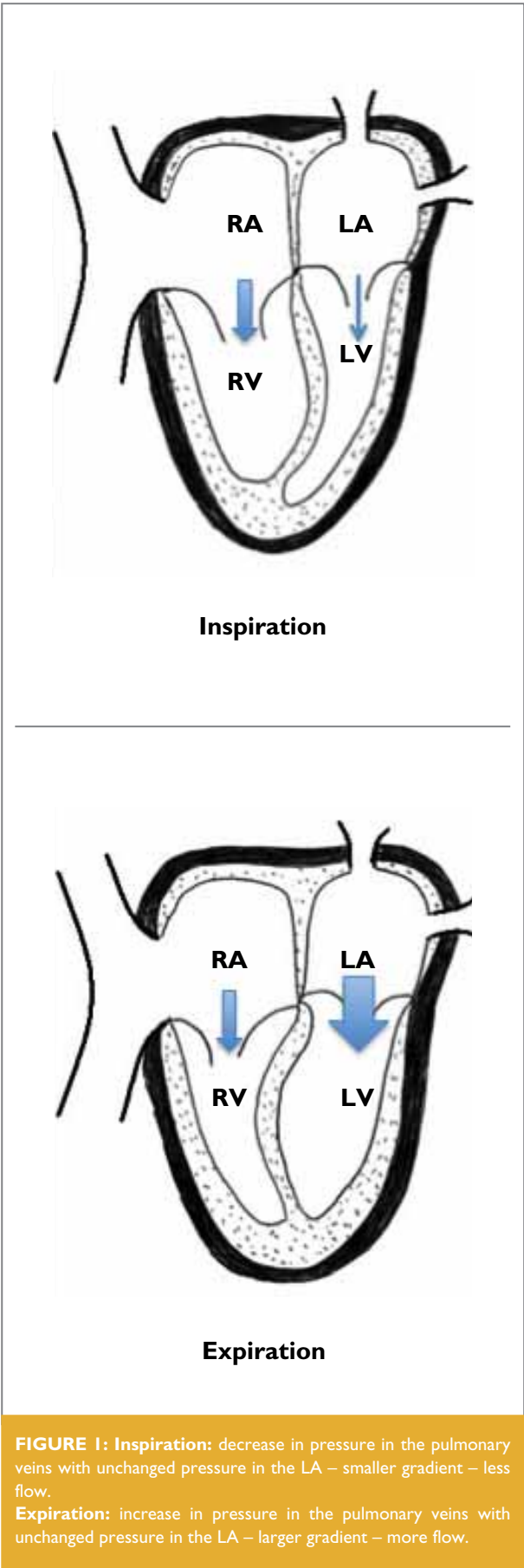


FIGURE 1: Inspiration: decrease in pressure in the pulmonary veins with unchanged pressure in the LA – smaller gradient – less flow.
Expiration: increase in pressure in the pulmonary veins with unchanged pressure in the LA – larger gradient – more flow.

fore degraded, leading to relative underfilling of the left heart, compared to the right, during inspiration. The IVC and SVC, responsible for right heart filling, are predominantly extra-thoracically positioned and are therefore, unlike the pulmonary veins, not subjected to the inspiratory decrease in intrathoracic pressure. Since the right heart is isolated from the pressure changes in the intrathoracic cavity by the thickened pericardium, filling of the right heart continues essentially unchanged during both inspiration and expiration. Given the fixed cardiac volume, with a fairly mobile septum separating the 2 chambers, right heart filling therefore occurs at the expense of the slower left heart filling during inspiration, with consequent respiratory septal shift into the left ventricle. During expiration, the opposite occurs (Figure 1). Due to the loss of pericardial compliance, the heart becomes reliant on elevated ventricular pressures to maintain cardiac filling, and this eventually leads to primary diastolic heart failure.

Our patient's raised JVP can easily be explained by the raised filling pressures in the right atrium. Given that the gradient for filling of the right heart remains unchanged with respiration, but a larger volume enters the right atrium during inspiration due to the relative underfilling of the left heart, the lack of an inspiratory decline (Kussmaul's sign) can also be explained. The prominent x-descent occurs due to the enhanced descent of the floor of the right atrium during systole, whereas rapid early diastolic flow into the right atrium, when the tricuspid valve opens, causes the prominent y-descent.

Due to the raised filling pressures, the heart fills rapidly early in diastole until its fixed volume is reached when filling comes to an abrupt halt, producing a sharp audible knock. This sound can be mistaken for a left ventricular S3, it however occurs earlier than a normal S3, is typically maximally heard along the left sternal border and is accentuated on inspiration. Respiratory variation in ventricular filling in constriction is responsible for the intensity of the knock becoming more pronounced at inspiration.

The palpable equivalent of the diastolic knock, or diastolic apex beat as it has been described, is commonly felt in this setting and can be a very prominent feature. In our experience this finding is often best felt over the epigastrium, but can be palpable anywhere over the precordium. We illustrated this clinical finding in a unique manner using the plethysmograph properties of a normal ear oximeter (Figure 2). The oximeter was placed on the patient's lower chest in the area of maximal diastolic pulsation, and the plethysmographic recording taken during a breath hold (note that the image was inverted to

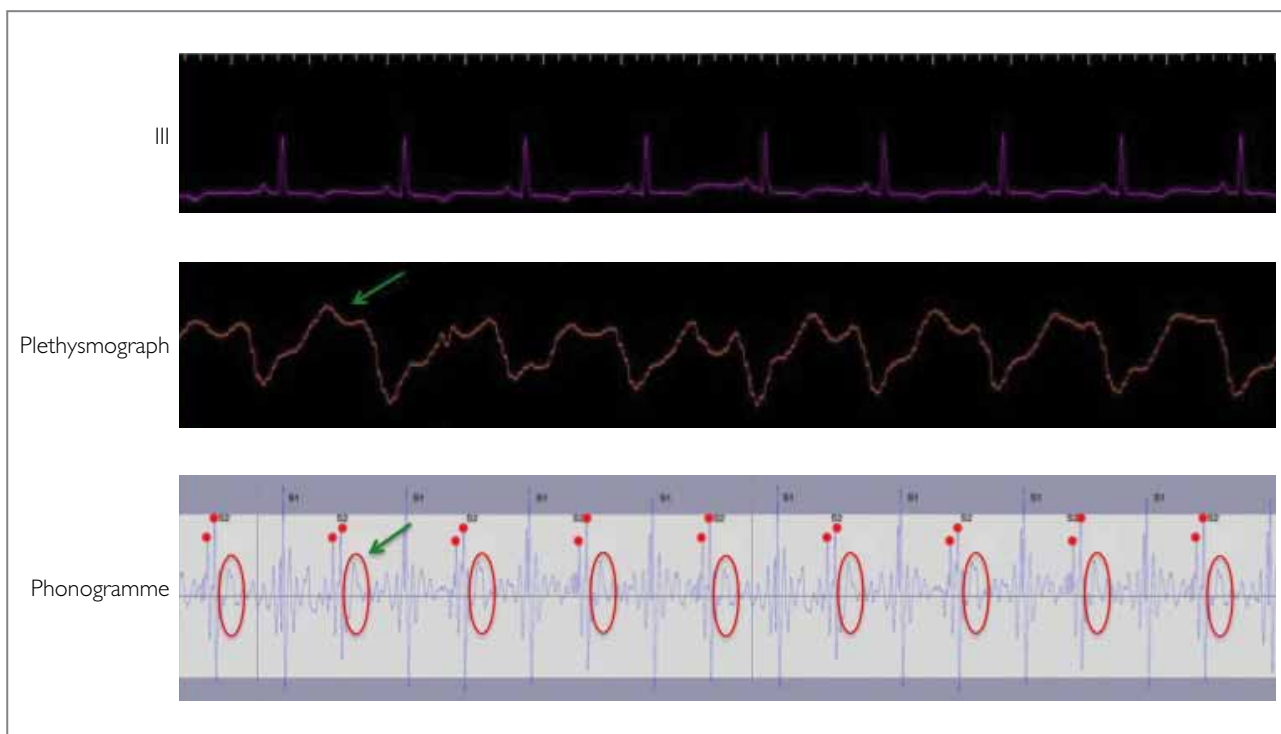


FIGURE 2: Graphic demonstration of a diastolic knock: Plethysmographic recording taken with a regular pulse oximeter during breath hold from the area of maximal diastolic pulsation (note that the image was inverted to account for the fact that the normal outward systolic pulse waveform records a negative deflection). An impulse can be seen to start just after the T-wave (early diastole; green arrow) with the entire impulse occurring in diastole, the opposite of what occurs with the normal apical impulse or a central arterial pulse. On the phonogramme above, an additional early diastolic heart sound (circled in red), representing an audible diastolic knock, can be seen coinciding with the plethysmographic impulse.

account for the fact that the normal outward systolic pulse waveform records a negative deflection). On the oximeter trace the impulse can clearly be seen to start just after the T-wave (early diastole; green arrow) with the entire impulse occurring in diastole, the opposite of what occurs with the normal apical impulse or a central arterial pulse. A phonograph trace, taken from the same patient, illustrates the timing of the knock on auscultation. This trace underlines the importance of timing the apex beat during any cardiac examination, especially in the setting of unexplained right heart failure.

CONCLUSIONS

A clinical examination technique is of paramount importance in the setting of possible constriction. Timing the apex beat remains a valuable part of the cardiac examination, particularly in the evaluation of a patient with unexplained right heart failure.

Conflict of interest: none declared.

REFERENCES

1. Faisal F. Syed, Hartzell V. Schaff and Jae K. Oh. Constrictive pericarditis: A curable diastolic heart failure. *Nat Rev Cardiol.* 2014;11:530-544.