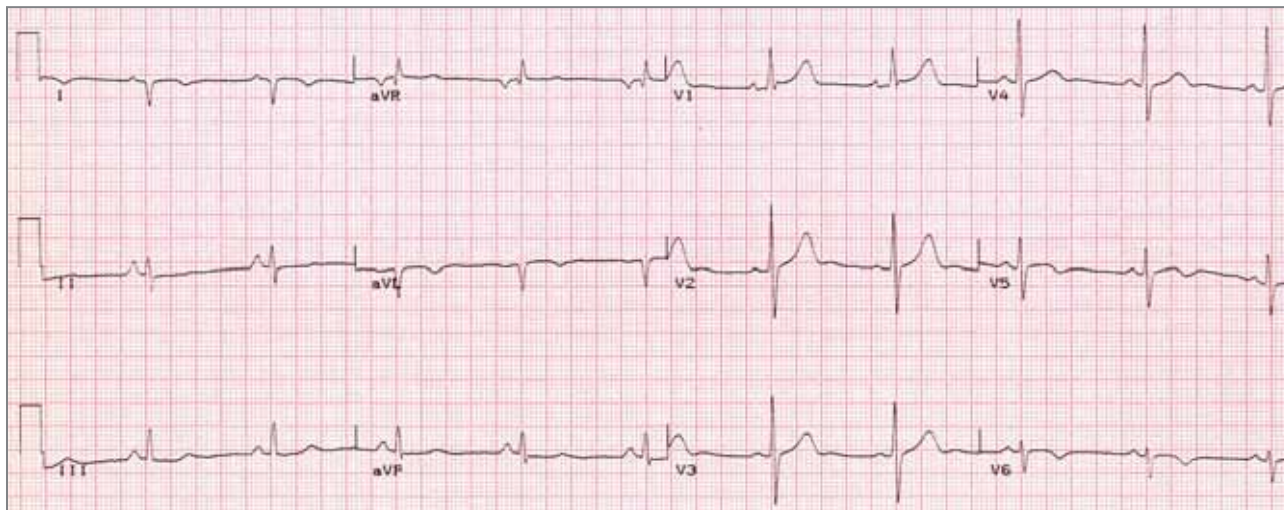


# ECG Quiz 42



**Rob Scott Millar and Ashley Chin**  
Cardiac Clinic, University of Cape Town /  
Groote Schuur Hospital  
Cardiac Arrhythmia Society of  
Southern Africa (CASSA)



**QUESTION: Which ONE of the following is the best ECG diagnosis?**

- a. Mirror image dextrocardia
- b. Posterolateral myocardial infarction
- c. Pre-excitation (WPW pattern)
- d. Right ventricular hypertrophy
- e. Left posterior fascicular block
- f. Limb leads misplaced

Please analyse the ECG carefully and commit yourself to an answer before checking the explanation.

**ANSWER** on page 128