

OVERVIEW OF THE ECG

There is a regular rhythm at 60bpm. The most obvious features are widespread ST depression and T wave flattening.

MORE DETAILED ANALYSIS OF THE ECG

The rhythm is sinus (P waves upright in II and inverted in aVR). The PR interval is normal (120ms). The QRS complexes are slightly wide (just <120ms - see V4). The axis is about +100° and the complexes are normal size with normal R wave progression. There are small septal Q waves in V5 - 6 and non-pathological Q waves in the inferior leads. The ST segments slope downwards from the J point and merge with inverted or biphasic T waves. The QT interval appears to be prolonged but is difficult to measure as it blends into a prominent U wave (the U wave amplitude exceeds the T wave amplitude in V3). The U wave is distinct from the T wave in V2 and most prominent in V4 - 6. The QT in V2 appears to be about 400ms, QTc 400ms. The QTU in V4 - 5 is 600ms.

In the absence of clinical information all the options listed should be considered.⁽¹⁾

Subarachnoid haemorrhage can cause a variety of ECG abnormalities (see ECG quiz 38⁽²⁾). However it typically causes marked bradycardia (due to raised intracranial pressure), marked T wave inversion (so-called “cerebral T waves” in contrast to hypokalaemia which causes a decrease in the T wave amplitude) and a prolonged QT. The QRS complex is usually unaffected (Figure 1A).

Ischaemic ST depression starts at the J point and slopes down. The QT interval is sometimes prolonged but the U wave is not usually prominent. Rarely, the U wave may be inverted (Figure 1C).

In **hypocalcaemia**, the ST segment is prolonged. The interval from the beginning of the QRS to the apex of the T wave (Q - aT) is prolonged, as is the QTc. Congenital LQTS Type III can produce a similar pattern (Figure 1D).

Congenital LQTS Type II tends to have bifid T waves - ST depression and prominent U waves are not usual features (Figure 1E).

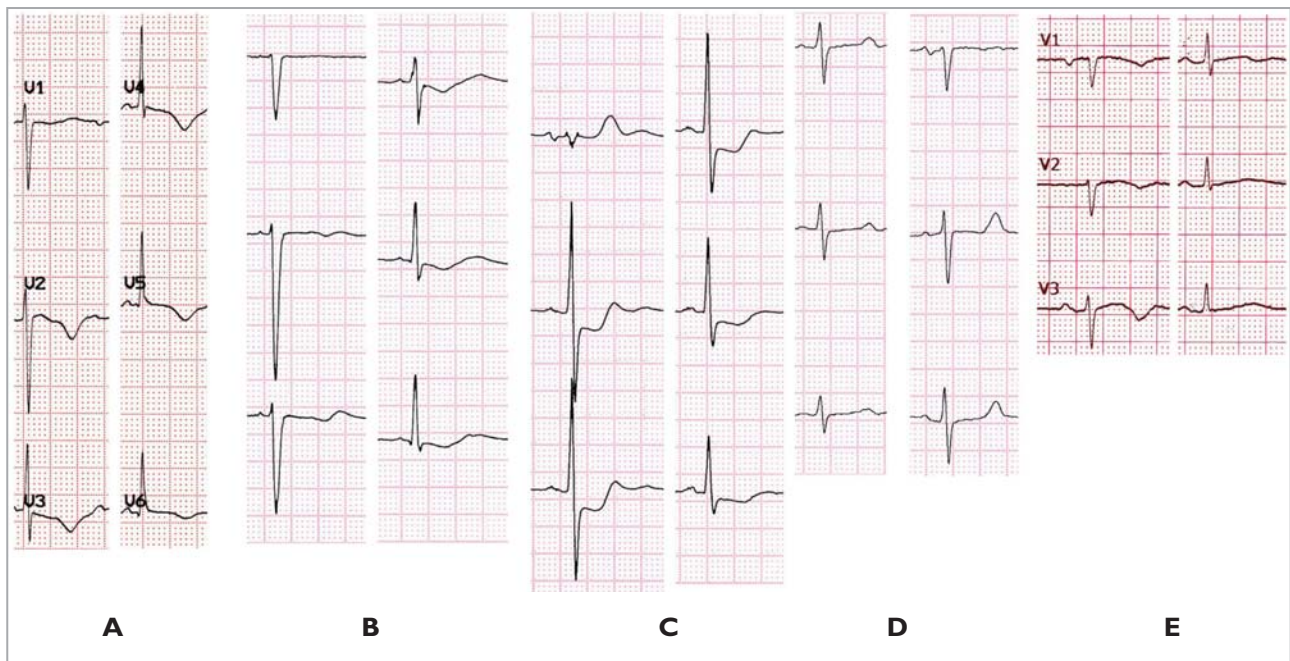


FIGURE 1: (A) Subarachnoid haemorrhage, (B) Hypokalaemia, (C) Ischaemic ST depression (D) Hypocalcaemia and (E) Long QT Syndrome Type II.

The pattern of slight QRS widening, ST depression, reduction in T wave amplitude and prominent U waves is typical of **hypokalaemia** (Figure 1B).

The correct answer is therefore (b): Hypokalaemia.

The patient was a 24-year-old woman with suspected laxative abuse. Her serum K⁺ was 1.8mmol/l. Her ECG normalised after administration of potassium chloride.

Hypokalaemia is most commonly encountered in the setting of diuretic therapy (loop or thiazide diuretics) when routine potassium supplementation is not administered.

Potassium is the major intracellular cation and the levels are tightly regulated between 3.5 and 5.0 mmol/l. Both hypokalaemia and hyperkalaemia can have electrophysiological effects that predispose patients to cardiac arrhythmias. Hypokalaemia (K⁺<3.5mmol/l) directly inhibits K⁺ channel conductances in the heart by inhibiting I_{K1}, I_{Kr} and I_{to} which results in prolongation of the action potential duration and the QT interval. Hypokalaemia also indirectly inhibits Na/K ATPase which results in intracellular calcium and sodium overload which predisposes to early after depolarisations and may induce torsade de pointes and ventricular fibrillation.⁽³⁾ Hypokalaemia is arrhythmogenic in itself but is most dangerous in the presence of potassium channel blocking drugs which prolong the QT.⁽⁴⁾

LESSONS AND CONCLUSIONS

- A variety of conditions can cause similar ECG patterns, particularly repolarisation abnormalities.
- Subtle differences help to distinguish the different patterns.
- The clinical context is key to their differentiation.

REFERENCES

1. Chou's Electrocardiography in Clinical Practice 6th ed. Eds. Surawicz B & Knilans TK, Saunders Elsevier 2008, Philadelphia.
2. Millar RS and Chin A. ECG quiz 38. SA Heart J 2015;12:88 & 92-95.
3. Weiss JN, Qu Z, Shivkumar K. Electrophysiology of Hypokalemia and Hyperkalemia. Circ Arrhythm Electrophysiol. 2017;10(3):e004667.
4. McKibben JK, Pocock WA, Barlow JB, et al. Sotalol, hypokalaemia, syncope and torsade des pointes. Br Heart J 1984;51:157-62.

Conflict of interest: none declared.