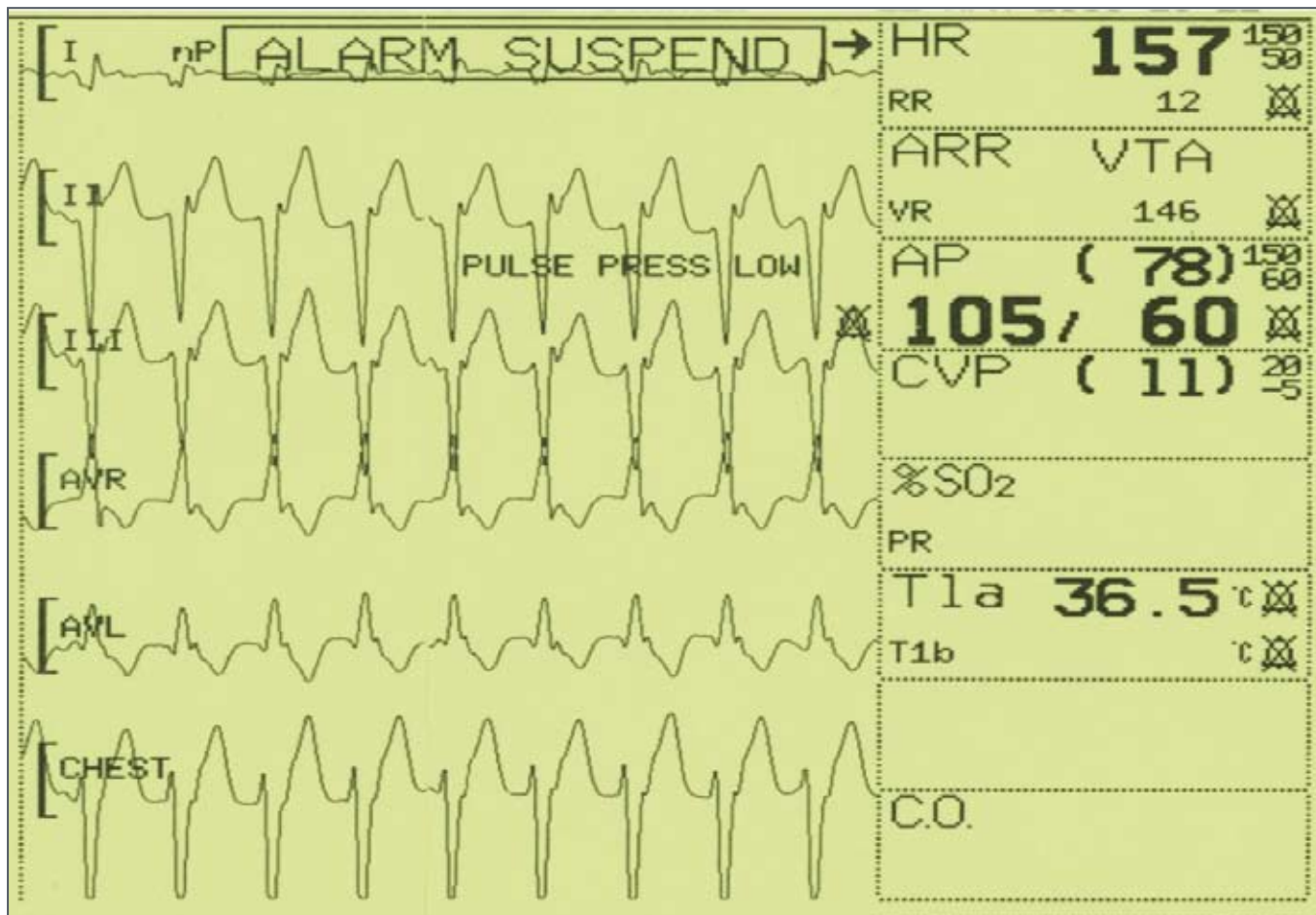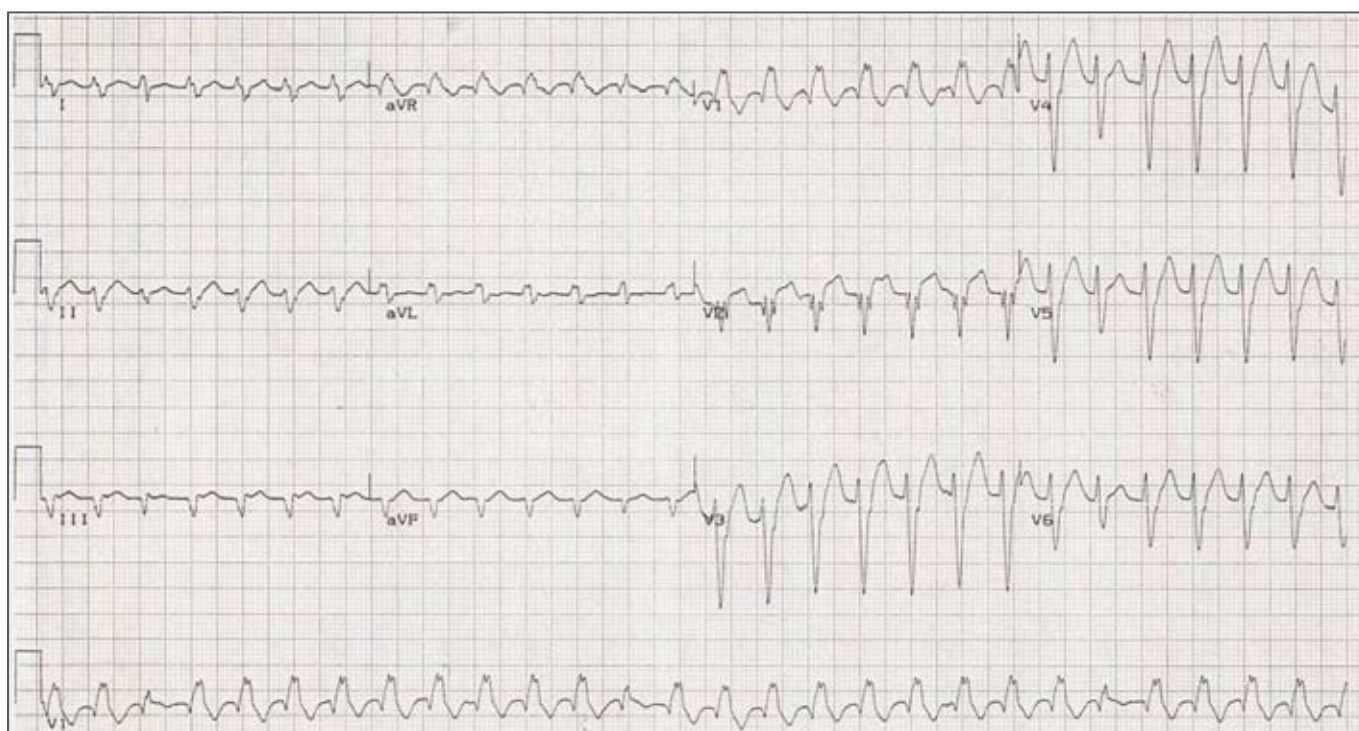


A call was received to assist with a patient in the surgical ICU with a tachycardia. He was a 48-year man who had earlier that day had uncomplicated coronary artery bypass graft surgery for unstable angina. He was being ventilated and receiving sedation and analgesia but no other drugs or inotropes. When the bedside monitor alarm went off with a heart rate >150bpm, the blood pressure was noted to be low. However, he did not respond to a fluid challenge. Also, cardioversion with 50J had no effect. The monitor screen is shown.

Clearly, treatment of this tachycardia depends on making the correct diagnosis. The diagnosis should not be made from the screen of the bedside monitor or the single channel of the defibrillator. To make a correct diagnosis of a tachycardia, the most important thing to do is to record a 12-lead ECG. Unless there is no cardiac output there is enough time for this most important investigation. So, a 12-lead ECG was recorded.



QUESTION: Having made the diagnosis, which **ONE** of the following is the best and safest treatment?

- (a) more analgesia
- (b) IV adenosine
- (c) repeat cardioversion
- (d) investigate and treat for pulmonary embolism
- (e) IV amiodarone

Please analyse the ECG carefully and commit yourself to an answer before checking the explanation.

ANSWER on page 190